

'De grootste misdaad tegen de mensheid' in de geschiedenis: Naomi Wolf's 11 onthullingen uit de Pfizer vaccin documenten

Door DissidentNL - 2023-04-28



'Dit zijn dus monsters, en we kunnen niet anders dan concluderen dat ze gericht zijn op het verstoren van de menselijke voortplanting', zei de auteur over de fabrikanten van de COVID-prik. 'Het is een biologisch wapen en... we worden aangevallen'.

In een buitengewone toespraak waarin verschillende "hoofd"-ontdekkingen uit analyses van duizenden Pfizer-documenten werden samengevat, presenteerde Dr. Naomi Wolf hoe de COVID-"vaccin"-onderneming opzettelijk probeerde niet alleen "de menselijke voortplanting te verstoren en aan te tasten" maar ook om grote aantallen mensen "aan te vallen en te doden", **vooral in het Westen**, meldt [Life Site News](#).

Wolf, een levenslange democraat, [sprak](#) in maart de conservatieve citadel van Hillsdale College toe en bekende dat de gebeurtenissen van de afgelopen drie jaar haar vroegere wereldbeeld "werkelijk implodeerden" en dat het belangrijkste nu "de grondwet en vrijheid" is.

De auteur en journalist die ook medeoprichter en CEO is van de [Daily Clout](#) legde uit hoe zij en Steve Bannon van de War Room 3.500 wetenschappelijke en medische experts rekruteerden om te helpen bij de analyse van tienduizenden [documenten](#) die Pfizer bij de FDA indiende voor gebruik bij de evaluatie van de veiligheid en effectiviteit van hun COVID-injecties.

De FDA had oorspronkelijk tegen hun vrijgave geprotesteerd in een Freedom of Information Act-rechtszaak om de publicatie van de cruciale veiligheidsgegevens tot **75 jaar** op te schorten, maar dit verzoek werd [afgewezen](#) door een rechtbank in Texas en de eerste documenten werden [vrijgegeven](#) op 2 maart 2022.

Deze 3.500 aangeworven experts werden verdeeld in zes werkgroepen met commissies aan het hoofd om de documenten te analyseren en [rapporten op te stellen die toegankelijk](#) en begrijpelijk zouden zijn voor het grote publiek.

En wat deze tientallen rapporten betreft, verontschuldigde Wolf zich bij voorbaat om te moeten meedelen dat deze Pfizer-documenten "bewijs bevatten van de grootste misdaad tegen de mensheid in de geschiedenis van onze soort."

Ze gaf een samenvatting van slechts "enkele dingen die aan het licht kwamen" en benadrukte de volgende 11 punten:

Een veel uitgebreidere uitwerking van de 11 punten hieronder staat bij [Life Site](#), maar omwille van de leesbaarheid vat ik het samen, [Dissident](#).

#1: Pfizer wist al in november 2020 dat hun op genen gebaseerde injecties een negatieve werkzaamheid hadden

#2: Kort nadat de COVID-injecties op de markt waren gebracht, nam Pfizer 2.400 fulltime medewerkers in dienst om het papierwerk van de gewonden te verwerken

#3: Pfizer en de FDA hielden gedurende vier maanden informatie achter dat de injecties hartschade veroorzaken bij jongeren, terwijl een agressieve propagandacampagne vele duizenden ertoe aanzette zich te laten injecteren

4: In plaats van op de injectieplaats te blijven, wist Pfizer dat de gevaarlijke lipidenodeeltjes van de injectie zich snel door het lichaam verspreiden. En er is geen bewijs dat ze ooit vertrekken

5: 'Ik zeg het niet lichtvaardig, maar het is massamoord': bijwerkingen in Pfizer-documenten veel ernstiger dan CDC en artsen vertelden patiënten

6: Voordat het legaal was, werden meer dan 1.000 kinderen geïnjecteerd en de documenten van Pfizer wijzen op een hoog percentage ernstig letsel

#7: Pfizer-documenten onthullen een 'experiment... over hoe de menselijke voortplanting kan worden verstoord en aangetast'. Beschikbare gegevens van studiedeelnemers die kinderen verwekten, laten zien dat 80% hun baby's verloor

8: Pfizer wist dat er een gevaar was voor de vruchtbaarheid. Lipide-nanodeeltjes beschadigen de placenta tijdens de zwangerschap en veroorzaken vroegtijdige bevallingen. Ook veel chromosomale afwijkingen

9: Documenten van Pfizer laten zien dat nanodeeltjes van lipiden ook in de moedermelk terechtkomen, waardoor baby's worden belemmerd, verwond en soms worden gedood

#10: 'Een oorlog tegen de vruchtbaarheid van vrouwen: documenten van Pfizer tonen 3 tot 1 van de AE's die door vrouwen worden opgelopen, 16% 'voortplantingsstoornissen'. 'Wat voor monsters kijken naar 16% voortplantingsstoornissen en gaan zo maar door?' Resultaten: '13% tot 20% daling in levendgeborenen'

11: LNP's degradeerden de basisfabrieken van mannelijkheid in de testikels van jongens in de baarmoeder wanneer hun moeder was geïnjecteerd. "Dus, dit zijn monsters, en er is geen manier om de conclusie te vermijden dat ze gericht zijn op het verstoren van de menselijke voortplanting"

Verder onthult Rapport 37 de schade die wordt toegebracht aan het voortplantingsvermogen van jongetjes in de baarmoeder van hun gevaccineerde moeders.

Wolf legde uit hoe de Pfizer documenten onthullen dat LNPs "jongetjes in de baarmoeder aantasten" door "de testikels van foetale jongetjes" te doordringen en "de Sertoli cellen en de Leydig cellen, die in feite de fabrieken van mannelijkheid zijn" te beschadigen.

Deze cellen "zijn verantwoordelijk voor de mannelijke hormonale balans die dingen creëert als diepe stemmen, haar op hun lichaam, brede schouders, alle dingen die we associëren met normale mannelijkheid. En dat wordt afgebroken.

"We weten dus niet of deze jongetjes van gevaccineerde moeders in staat zullen zijn op te groeien tot seksueel functionerende volwassen mannen," waarschuwde ze.

Bovendien, "Waarom deze focus op voortplanting?" vroeg Wolf. Waarom onderzocht en documenteerde Pfizer het effect van hun injectiemiddel op de "geslachtscellen van de geslachtsorganen van de ratten, toch? Het is een ademhalingsvirus.

“Dus, deze [mensen] zijn monsters, en er is geen manier om niet te concluderen dat ze gericht zijn op het verstoren van de menselijke voortplanting,” concludeerde ze.

Help ons de censuur van BIG-TECH te omzeilen en volg ons op Telegram:

Telegram: t.me/dissidenten

Meld je aan voor onze gratis dagelijkse nieuwsbrief, 10.000 gingen je al voor:

Het is meer bepaald een aanval op het voortplantingsvermogen van het Blanke ras. In Afrika is slechts 7% gevaccineerd. China heeft Pfizer goedgekeurd maar nooit gebruikt. India heeft Pfizer het land uitgezet toen het bedrijf de veiligheidsonderzoeken niet wilde laten zien. Het komt bovenop alle andere aanvallen op het Blanke ras; omvolkingsimmigratie, de Pil, feminisme, vrije seks, de LGBTQ-hysterie. Dat wetende zou je jezelf een simpele vraag moeten stellen...

DissidentNL

Als ze je kunnen verplichten een vaccin te nemen, kunnen ze je ook verplichten je te laten steriliseren, euthanasie te plegen of op verzoek een orgaan af te staan. Als je lichamelijke integriteit geschonden kan worden door de overheid dan kunnen ze alles met je doen. Dan ben je feitelijk een slaaf.

NEWS

'The greatest crime against humanity' in history: Naomi Wolf's 11 revelations from Pfizer vaccine documents

'So, these are monsters, and there's no way to avoid concluding that they're focused on disrupting human reproduction,' the author conceded about the manufacturers of the COVID jab. 'It's 'a bioweapon and... we're under attack.'



Naomi Wolf

Rumble

Patrick Delaney

Mon Apr 24, 2023 - 10:34 pm EDT

(LifeSiteNews) — In an extraordinary speech synthesizing several “headline” discoveries from analyses of thousands of Pfizer documents, Dr. Naomi Wolf presented how the COVID “vaccine” enterprise intentionally sought to not only “disrupt and impair human reproduction” but “attack” and “kill” large numbers of people, particularly in the West.

Wolf, a lifelong Democrat, addressed the conservative citadel of Hillsdale College in March, confessing that events over the last three years “truly imploded” her former world view and that what matters most now is “the Constitution, liberty and freedom.”

The author and journalist who is also a co-founder and CEO of the Daily Clout explained how she and Steve Bannon of the War Room recruited 3,500 science and medical experts to help analyze tens of thousands of documents that Pfizer submitted to the FDA for use in evaluating the safety and effectiveness of their COVID injectables.

The FDA had originally argued against their release in a Freedom of Information Act lawsuit seeking to stall publication of the crucial safety data for up to 75 years, but this request was rejected by a Texas court and the first drop of documents were released on March 2, 2022.

These 3,500 recruited experts were divided into six working groups with committees at the head of them to analyze the documents and create reports that would be accessible, and understandable, to the general public.

And regarding these dozens of reports, Wolf apologized in advance for having to share that these Pfizer documents “contain evidence of the greatest crime against humanity in the history of our species.”

Providing a summary of just “some of the things that came to light,” she highlighted the following 11 points:

#1: Pfizer knew their gene-based injections had negative efficacy as early as November 2020

At least as early as May 2021, five months after the rollout of the Pfizer gene-based injections, reports began to emerge of many “breakthrough cases” where fully jabbed celebrities and then the public at large were being inflicted with cases of COVID-19. By October, studies began to confirm the ineffectiveness of the shots, and then later, by January 2022, that those who were jabbed against COVID-19 were more likely to catch it.

These findings continued to be confirmed in July 2022, December 2022, and then in January as well.

Yet, according to the analysis of the data, Wolf stated that Pfizer knew this was the case with regard to their own product in November 2020 before being broadly introduced and marketed as a remedy for COVID-19.

“Pfizer knew, for instance, one month after rollout, so that’s November of 2020, that the vaccines didn’t work to stop COVID!” she exclaimed.

She recalled how during this period the full marketing of the product was in swing, with the celebrity spokespeople encouraging all to get the shot. “The ads are in social media, the ads are on television” and “a month after rollout, Pfizer’s internal documents identify that its vaccines have vaccine failure and failure of efficacy. And they identify that the third most common side effect of the Pfizer vaccine is... COVID!”

#2: Shortly after release of the COVID injections on the market, Pfizer moved to hire 2,400 full-time employees to process the paperwork of the injured

In a January 2021 white paper analyzing the new COVID “vaccines,” America’s Frontline Doctors observed how and why the safety of such an intervention had to be assured before its being used, especially on a global population.

“In contrast to taking a medication for an actual disease,” they explained, “the person who takes a vaccine is typically completely healthy *and would continue to be healthy without the vaccine*. As the first rule of the Hippocratic Oath is: do no harm, vaccine safety must be *guaranteed*. That has not yet happened,” they observed at the time.

In her group's examination of the Pfizer documents, Wolf declared that what was "stunning" is that around this same time, "within a month or two [of vaccine rollout], Pfizer was getting so many reports of adverse events [AEs] – meaning bad things happening to people who had been injected – that they understood they needed to hire 2,400 full-time staffers in order simply to process the paperwork" of these injuries. They also knew this was necessary "to prepare for the flood of adverse events that they knew they would get in the near future."

Of course, many months later, evidence reveals correlations of the shot mandates with enormous increases in younger excess deaths and disabled workers, which in the United States equates to those under age 50 who took the shots having a 49 percent higher mortality rate, including all categories of the jabbed suffering a 26 percent increase. All of this results in about 600,000 excess deaths per year and a historic decline in life expectancy.

#3: Pfizer and the FDA withheld information that the shots cause heart damage in youth for four months while an aggressive propaganda campaign drove many thousands to get injected

“Pfizer knew in May of 2021 that the vaccines had caused heart damage in 35 minors within a week after the injection,” Wolf explained. This information was known by the U.S. Food and Drug Administration (FDA) as well, as the documents were in their possession.

“But the government of the United States – and I’m embarrassed to say I voted for these people – didn’t tell parents until August of 2021 that there was an elevated risk of heart damage in healthy young adults. Four months later!” she exclaimed.

“And in those four months, what did the young adults of America receive? A constant battering with propaganda on social media, on television, in news outlets bought up by money in the CARES Act, as well as from the Bill and Melinda Gates Foundation,” Wolf explained. “They did not tell the young adults, the healthy young adults of the United States, your generation, that this was elevating a risk of heart damage till four months later.”

#4: Rather than staying in the injection site, Pfizer knew the shot’s dangerous lipid nanoparticles quickly distribute throughout the body. And there is no evidence they ever leave

“You may recall that the CDC said that the materials of the injection stay in the injection site,” the journalist said. “And the materials are lipid nanoparticles, they are mRNA,” which means they are “industrial fat which is covered in polyethylene glycol, which is a petroleum byproduct... and spike protein.”

Yet, while it was broadly propagated that these dangerous substances stay in the injection site, “that’s not what happens to these materials! And Pfizer knew that! These materials ‘biodistribute’ – this is *Pfizer’s language* – throughout your body in 48 hours!” Wolf exclaimed.

First describing how “lipid nanoparticles [LNPs] are designed to cross every membrane in the human body,” which has been known for at least a decade, Wolf asked, “So where do these ingredients go?”

“They go to the brain (some of you have noticed changes in the personalities of loved ones who have taken these injections). They biodistribute to the liver, the adrenals, the spleen. And if you’re a woman, they accumulate in your ovaries,” she lamented.

“Now, these are industrial fats coated with polyethylene glycol in your ovaries,” Wolf warned. “And what’s incredibly scary for a woman is that there’s no mechanism that we’ve found by which the body gets rid of the lipid nanoparticles in the ovaries... And Pfizer knew [this].”

#5: ‘I don’t say it lightly, but it’s mass murder’: Side effects in Pfizer documents far more severe than CDC and doctors told patients

The Pfizer documents acknowledge more than 42,000 adverse events, including 1,200 deaths, in just the first three months due to what Wolf describes as “catastrophic categories” of side effects that go far beyond typical warnings given by public health authorities.

“These are not the same side effects that the CDC tells you about or your doctor tells you about,” Wolf recalled. While the CDC has often typically said recipients will have fatigue, chills and perhaps swelling at the injection site, “that’s not what’s in the Pfizer documents.”

Rather, “there’s industrial scale strokes, hemorrhages, blood clots, lung clots, leg clots, neurological disorders, dementia-type disorders. Guillain-Barré, Bell’s Palsy [and more].”

“The number one side effect is joint pain,” she said. “Did the CDC tell you about joint pain?” And another “surprising side effect is myalgia, muscle pain,” of which Wolf said she has friends now enduring, despite their prior excellent health. And this side effect is indicated “at industrial scale in the Pfizer documents.”

“I don’t say it lightly, but it’s mass murder,” she grieved. “There are 61 deaths from stroke, for example. Half of the stroke adverse events took place within 48 hours of the injection. They’re five deaths from liver damage and half of the liver damage adverse events took place within 48 hours of the injection.”

#6: Prior to it being legal, more than 1,000 children were injected, and Pfizer’s documents indicate a high rate of serious injury

In early 2021, before any Emergency Use Authorization (EUA) for children, Wolf reported that Pfizer injected “62 kids, some of them as young as two months old,” with their gene-based product, 28 of whom there were no records of the results available. “We don’t know if they survived,” she said.

“Among the 34 whose records are still in the Pfizer documents, there’s a seven-year-old British girl who sustained a stroke, and there’s a two-month-old baby with liver damage,” she lamented.

“And so this is such a chilling report because it’s clear – and we did additional investigation of this – there were a thousand kids in the United States in different university hospitals, including Rochester Medical Center, that were experimented on prior to it being legal to inject children with this material,” the author lamented.

“And I can promise you, these are what society calls ‘throwaway kids.’ These are not kids whose parents have lawyers. These are not kids whose parents have a voice. We’re going to find that these are kids who are institutionalized, who are orphaned or discarded in some way,” she grieved.

#7: Pfizer documents reveal a ‘Mengele-type experiment... on how to disrupt and impair human reproduction.’ Available records of study participants who conceived children show 80% lost their babies

Highlighting what she calls “the centerpiece of what we found in the Pfizer documents,” Wolf explained that she doesn’t make reference to Nazi medical experimentation lightly, but contained in the documents is “literally [a] Mengele-type experiment at a grand scale on human reproduction, [a] 360-degree experiment on how to disrupt and impair human reproduction.”

“So, for example, in the Pfizer documents, women study participants were told not to get pregnant, which is interesting,” she observed. “It’s a respiratory disease. Why would you tell women not to get pregnant?”

Nevertheless, 270 women did conceive children of whom Pfizer reportedly “lost the records” of 234, which Wolf said is a violation of the law.

“Of the 36 [remaining] women whose pregnancies came to term, over 80 percent of them lost their babies [by] spontaneous abortion or miscarriage,” she reported.

#8: Pfizer knew there was a danger to fertility. Lipid Nanoparticles damage the placenta during pregnancy, causing early deliveries. Lots of chromosomal abnormalities as well

In addition, the Pfizer documents indicate that “shedding is real,” Wolf reported. “Pfizer defines exposure to the vaccine as skin contact, inhalation and sexual intercourse, especially [at the time of] conception.”

Since Pfizer also warned male trial participants against having sexual intercourse with childbearing-aged women and to use two forms of birth control if they did, “there was clearly something about conceiving with a vaccinated male that Pfizer was guarding against,” she said.

“So, we know now that there’s horrific damages to conception from this injection” which include the lipid nanoparticles traversing the placenta and causing children to be born prematurely, Wolf said.

She also reported that maternal fetal medicine specialist, Dr. Jim Thorpe, is “seeing, at great scale, chromosomal abnormalities in newborns of vaccinated mothers.”

These results were foreseen by some, including former Pfizer vice president and chief scientist for allergy and respiratory Dr. Michael Yeadon, who, on December 1, 2020, petitioned the European Medicines Agency to halt all studies due to safety concerns, including possible damage to placentas during pregnancy. His warnings went unheeded. And though having been vilified, he has now been, unfortunately for all, vindicated.

#9: Pfizer docs show that lipid nanoparticles also enter breast milk, stunting, injuring and sometimes killing babies

Since these dangerous LNPs circulate throughout the body, especially in the recipient's blood, Wolf explained that they make their way into breast milk.

“And nursing babies, in the Pfizer [trial] documents, sustained seizures and one baby died in the E.R. after nursing from a vaccinated mother, from multi-organ system failure,” she said. “Four of the moms, who were lactating... had breast milk that turned blue green.”

After the release of these injections into the general population, incidents of these adverse events began to publicly emerge.

One VAERS report from February 2021 describes the death of a five-month-old breast-fed infant whose mother received a second dose of Pfizer's jab. The following day, the baby refused to nurse, developed a fever, and was later hospitalized with a rare blood disorder in which blood clots form in small blood vessels throughout the body before dying.

And in June 2021, a six-week-old breastfeeding baby became inexplicably ill with a high fever after his mother received a COVID-19 vaccine and he died weeks later with blood clots in his “severely inflamed arteries.”

Wolf went on to explain that even the National Institutes of Health (NIH) completed a separate study that found “babies nursing from vaccinated moms were having failure to thrive, not putting on weight. They were agitated and restless and sleepless.”

She believes that these dynamics have provide an indication as to why “nursing mothers have gone, in the last two years, from 34 percent of all moms to 16 percent of moms,” which indicates “something’s wrong.”

“Not only are babies in the next generation not getting that primal experience of total love, total nurture, total safety, which is so important, but there’s something that is leading moms to not be able to nurse those babies. And I think we have a clue here in the contamination of vaccinated moms’ breast milk,” Wolf opined.

“I also want to note that Bill Gates rolled out lab-grown breast milk right at the moment that women were suffering these harms to their own ability to sustain their children,” the feminist author said (more here).

#10: 'Nazi medicine,' a war on women's fertility: Pfizer docs show 3 to 1 of AEs sustained by women, 16% 'reproductive disorders.' 'What kind of monsters look at 16% reproductive disorders and keep going?' Results: '13% to 20% drop in live births'

In examining the thrust of the Pfizer documents, Dr. Wolf concluded that an overall motive behind this enormous enterprise includes “a war against women’s ability to reproduce.”

Her team “found that of the adverse events, 72 percent of them were sustained by women. And this is constant throughout. It’s a constant 3 to 1 [ratio]” she said while also acknowledging the real harms done to men ([Report 38](#)).

“And of the 72 percent of adverse events” in women, Pfizer defines 16% of them as, “[in] their words, ‘reproductive disorders,’” while men also suffer a terrible rate but far less at 0.49 percent.

“What kind of monsters look at 16 percent reproductive disorders [in their trials] and keep going?” the longtime feminist charged.

She goes on to call the Pfizer records reminiscent of “Nazi medicine” due to how detailed their records were regarding the hundreds of thousands of adverse attacks against the reproductive organs of women. For example, the records reflect “20 different scientific names for ruining women’s menstrual cycles” she said.

“Not surprisingly, in 2022, around the world, nine months after the rollout in most of Western Europe, there’s a 13 percent to 20 percent drop in live births all over Western Europe, in North America, [in] Singapore and Australia,” she explained.

This includes “double the number of stillbirths in Scotland, a highly vaccinated country, [and] 89 stillbirths in Canada in one province when usually they have two or three,” Wolf grieved.

Calling this phenomenon an “absolute baby die-off,” the journalist went on to cite the experience of Dr. James Thorp saying how he was now experiencing “five or six miscarriages a week when before they would have two a month.”

This phenomenon is “not universal,” Wolf shared. “This drop, this murder of the next generation, is not global. It’s [focused in] Western Europe and North America.”

#11: LNPs degraded the basic factories of masculinity in boys' testes in utero when their mother had been injected. 'So, these are monsters, and there's no way to avoid concluding that they're focused on disrupting human reproduction'

Furthermore, Report 37 reveals the damage done to the reproductive capacities of baby boys in their vaccinated mothers' wombs.

Wolf explained how the Pfizer documents reveal that LNPs “degrade baby boys in utero” by traversing “the testes of fetal baby boys” and damaging “the Sertoli cells and the Leydig cells, which are basically the factories of masculinity.”

These cells “are responsible for the male hormonal balance that create things like deep voices, hair on their bodies, broad shoulders, all of the things that we associate with normal masculinity. And that is being degraded.”

“So, we don't know if these little baby boys of vaccinated moms are going to be able to grow up to be sexually functioning adult men,” she warned.

Additionally, “Why this focus on reproduction?” Wolf asked. Why did Pfizer examine and document the impact of their injectable on the “sexual cells of the sexual organs of the rats, right? It’s a respiratory virus!”

“So, these [people] are monsters, and there’s no way to avoid concluding that they’re focused on disrupting human reproduction,” she concluded.

‘We are under attack’ with a ‘bioweapon,’ it’s ‘a mass murder situation, a war, a war crime, [and] crimes against humanity’

Wolf goes on to give her personal judgments as to why this is happening, particularly in the West, and advances a conclusion similar to former pharmaceutical executive and researcher Sasha Latypova and paralegal journalist Katherine Watt, asserting that these COVID vaccines are “a bioweapon and we are under attack.”

Over the last six months, Latypova has determined through extensive documentation that U.S. government agencies, particularly the Department of Defense, along with the pharmaceutical companies and Chinese Communist Party (CCP), are involved in “a conspiracy to commit mass murder through bioterrorism and informational warfare operations worldwide.”

Echoing their findings, Wolf explained how CCP-affiliated Fosun Pharmaceutical plays a significant role in developing and distributing the Pfizer/BioNTech biological warfare agents that are marketed as “COVID-19 vaccines.”

She explained that the CCP owns the manufacturing plants “producing the injection that goes into the bodies of schoolchildren here in the United States of America,” and further how studies overseen by the CCP reveal they knew full well that LNPs damage fertility and cause myocarditis.

“To me, it is obvious,” she said, that these investigative studies were intended “to show the Chinese Communist Party how you kill Westerners without leaving fingerprints.”

Speaking of the American government’s culpability, Wolf asserted that “this is a captured [Biden] administration and captured institutions that are allowing the CCP and their allies, the World Economic Forum, [and the] Bill and Melinda Gates Foundation, to cripple our country.”

Emphasizing how the CCP prefers “asymmetric warfare” tactics that “kind of degrade and demoralize the [enemy] population rather than having a hot war with shooting,” the author showed how the vast majority of approximately 42,000 adverse events recorded in the Pfizer documents occurred in the Western nations.

“That’s targeting North America and Western Europe,” she emphasized.

“I believe we’re looking at a mass murder situation, a war, a war crime, [and] crimes against humanity,” Wolf assessed. And with regard to “all of these evil doers” who are responsible, “friendly as they look in their little outfits, talking to the cameras,” the author disclosed, “I hope they will all face justice in this lifetime.”

Possible treason charges; Canadian doctor: ‘It’s a time to put these bastards in jail’

In service to this end, Watt has produced what she calls a “[r]esearch and organizing tool” providing evidence for the stated goal “to prosecute members of Congress, presidents, HHS and DOD secretaries and federal judges for treason under 18 USC 2381.”

Late last year, prominent Canadian medical doctor Roger Hodkinson exclaimed he was “full of vengeance” against these culprits and “it’s a time to put these bastards in jail.”

“We’ve seen the biggest kill ever in medicine’s history directly because of the intervention of these idiots into health care. And it’s the physicians, it’s not just the politicians, it’s the physicians themselves who are principally culpable because they have allowed [the] government’s jackboots to influence how they manage their patients, which has never, ever happened before,” he said.

“How can you look into the eyes of a pregnant woman and tell her that this experimental product is safe? How can you do that as a physician?!” the biotech CEO exclaimed. “Any physician that has done that should be in jail!”

‘If my people... will humble themselves and pray and seek my face... I will forgive their sin and heal their land’

Facing what she described as “this abyss of human evil every single day” over the last few years, Wolf also shared how the experience has forced her to take the reality of God much more seriously.

“I know that sounds paradoxical, but I felt like this evil overtook the world in lockstep, in perfect unison in a way that I could not explain using my critical thinking,” she assessed. There was “something metaphysical about” what happened.

Feeling the world is facing “a biblical moment where humanity is being asked to choose,” Wolf, who is Jewish, has taken up reading the Bible “a lot these days,” and ended her presentation reminding her Christian audience of the promise God gave to Solomon in 2 Chronicles 7:14:

If my people, who are called by my name, will humble themselves and pray and seek my face and turn from their wicked ways, then I will hear from heaven, and I will forgive their sin and heal their land.

RELATED

[Naomi Wolf: COVID jab is a ‘bioweapon’ aimed at depopulating the West](#)

[Giving experimental COVID jabs to pregnant women has been the greatest medical disaster in history](#)

[Naomi Wolf: We are at the final stage before tyrannical leaders ‘crush democracy’](#)

Naomi Wolf argues COVID shots are causing excess deaths among newborns and unborn babies

EXCLUSIVE: Ex-Clinton adviser banned from Twitter: Deplatforming is 'terrifying' for democracy

TOPICS

Bioethics

Coronavirus

Culture of Life

Demographics

Freedom

Politics - Canada

Politics - U.S.

Politics - World

Population Control

TAGGED AS

Alexandra Latypova

Bioweapons

Ccp

COVID shot

Daily Clout

Hillsdale College

James Thorp

Katherine Watt

Michael Yeadon

Mrna Vaccine

mRNA vaccines

Naomi Wolf

Pfizer

Roger Hodgkinson

war room

CLAIM: Pfizer heeft meer dan 400 "onafhankelijke" medische organisaties en non-profitorganisaties omgekocht om valse verhalen over hun zogenaamde vaccin te verspreiden

Door DissidentNL - 2023-04-27



Toen de misdaden tegen de menselijkheid in maart 2020 werden geëscaleerd onder het mom van een nooit eindigende "nationale noodtoestand", verstrekke de federale regering een eindeloze geldstroom aan multinationale organisaties die een geschiedenis van misdadig gedrag hebben (vaccinfabrikanten). Deze eindeloze fondsen zijn niet gebruikt om veilige en effectieve behandelingen, profylactica en immunisaties te ontwikkelen.

In plaats daarvan zijn deze fondsen grotendeels gebruikt om artsen, medische scholen, media, non-profitorganisaties, "onafhankelijke" organisaties en burgerlijke vrijheden groepen om te kopen [om valse en misleidende verhalen te verspreiden](#) over een mRNA genetische "therapie" die een vermomd biowapen bleek te zijn, [schrijft Lance D Johnson](#).

De Chicago Urban League nam 100.000 dollar aan steekpenningen aan van Pfizer, verraadde de mensen die ze beweren te beschermen

In de hele Amerikaanse samenleving steunden medische en burgerrechtengroepen in brede zin en eenzijdig de zogenaamde "covid-19-vaccins" en een spervuur van onwettige mandaten. Het blijkt dat deze brede steun voor medische fraude en segregatie was omdat Pfizer meer dan 400 medische instellingen, organisaties en verenigingen omkocht om hun vuile werk te doen.

Toen bijvoorbeeld Karen Freeman-Wilson, voorzitter van de Chicago Urban League, op televisie kwam om aan te dringen op vaccinatieplicht voor alle werknemers in Chicago, wuifde ze de ernstige bezorgdheid weg dat de mandaten de zwarte gemeenschap onevenredig zouden schaden. "De gezondheids- en veiligheidsfactor weegt veel zwaarder dan de zorg om mensen buiten te sluiten of een barrière op te werpen," zei [Freeman-Wilson in augustus 2021 op WTTW](#).

Eerder dat jaar had de Chicago Urban League 100.000 dollar subsidie (steekpenningen) ontvangen van Pfizer, voor een "project" waarbij de organisatie de "veiligheid en effectiviteit van vaccins" moest promoten. Ze voelde zich gedwongen om "de gezondheid en veiligheid" voor iedereen verplicht te stellen, omdat ze was betaald om deze leugen te verspreiden. Hoewel Pfizer [wist dat hun zogenaamde vaccin niet werkte en niet veilig was](#), hadden ze de middelen die ze nodig hadden om prostituees te maken van medische organisaties en zelfs burgerrechtenorganisaties.

De Chicago Urban League werd omgekocht door Pfizer om precies die inwoners van Chicago te verraden die ze pretenderen te beschermen. Bovendien maakt de League normaal gesproken haar zakelijke donoren bekend, maar deze keer maakten ze de financiering die ze kregen van Pfizer niet bekend in hun "partners" sectie op hun website. Ook Freeman-Wilson maakte haar belangenconflict met Pfizer niet bekend toen ze publiekelijk opriep tot onwettige vaccin mandaten voor alle werknemers van Chicago.

"Onafhankelijke" organisaties die vochten voor vaccinpaspoorten en mandaten werden omgekocht door de vaccinindustrie.

Pfizer heeft alle organisaties opgesomd die zij hebben omgekocht in hun [US Medical, Scientific, Patient and Civic Organization Funding Report](#). Volgens hun eigen financiële gegevens verstrekke Pfizer speciale financiering aan non-profit en handelsorganisaties die lobbyden voor overheidsbeleid dat covid-19 vaccins wilde verplichten.

Het Immunization Partnership bijvoorbeeld, een non-profit op het gebied van volksgezondheid in Houston, Texas, nam in 2021 35.000 dollar smeergeld aan van Pfizer voor "wetgevende belangenbehartiging". In plaats van in te gaan op de slopende bijwerkingen van Pfizer's covid prik en het onvermogen om besmetting te stoppen, bleef de non-profit de leugens van Pfizer aanvoeren en [viel zelfs](#)

publiekelijk de wetgeving in Texas aan die vaccinatiepaspoorten- en -plicht wilde blokkeren. Het Immunization Partnership beweerde dat de wetsvoorstellen "de vitale rol van de volksgezondheids- en medische experts van onze staat in de strijd tegen deze pandemie uithollen". Twee jaar later zijn het organisaties als Immunization Partnership die zich aantoonbaar hebben overgegeven aan medische fraude en misleiding, en hebben deelgenomen aan allerlei schendingen van mensenrechten, om uiteindelijk het vertrouwen van het publiek in medische en volksgezondheidsdeskundigen uit te hollen.

De agressieve propaganda achter de [covid-19-vaccinatieplicht](#) is te wijten aan een onderliggende en alomtegenwoordige lafheid die bestaat in de leidinggevende posities van honderden 'onafhankelijke' organisaties in de hele Amerikaanse samenleving. Veel van deze laffe leiders maakten zelfs de Pfizer-financiering niet bekend, terwijl ze een onethisch beleid van onderwerping, discriminatie en segregatie voortzetten dat arbeiders dwongen om meerdere injecties te krijgen die niet werkten en verdere schade aanrichtten.

Help ons de censuur van BIG-TECH te omzeilen en volg ons op Telegram:

Telegram: t.me/dissidenten

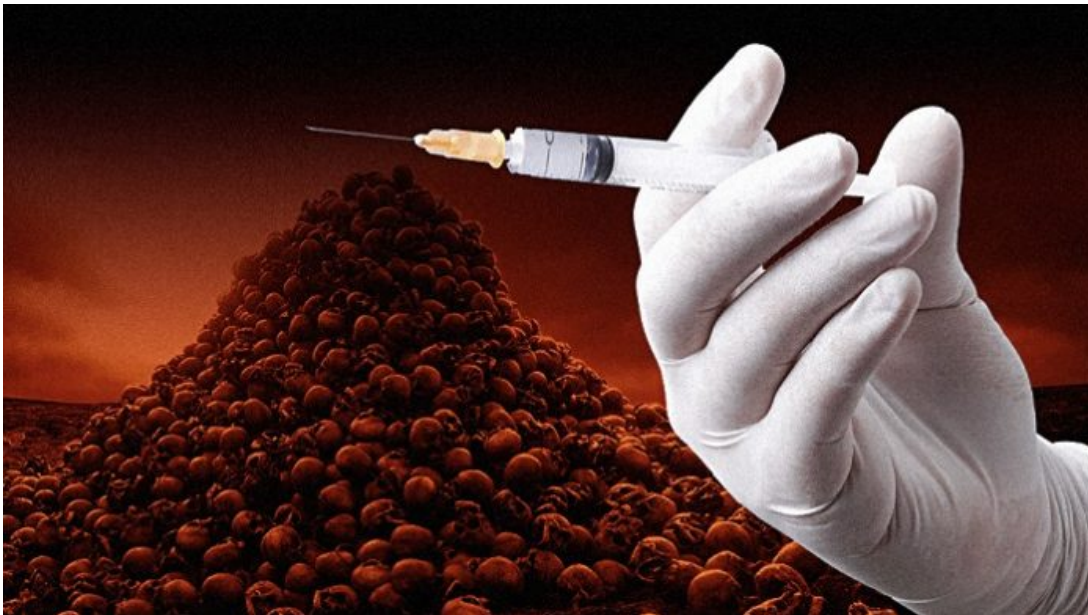Meld je aan voor onze gratis dagelijkse nieuwsbrief, 10.000 gingen je al voor:

DissidentNL

Als ze je kunnen verplichten een vaccin te nemen, kunnen ze je ook verplichten je te laten steriliseren, euthanasie te plegen of op verzoek een orgaan af te staan. Als je lichamelijke integriteit geschonden kan worden door de overheid dan kunnen ze alles met je doen. Dan ben je feitelijk een slaaf.

WAARSCHUWING: "Vaccin is erger dan we vreesden, kunnen honderdduizenden meer doden verwachten"

Door DissidentNL - 2022-01-13



Mensen die de experimentele injecties krijgen, lijken er veel slechter aan toe te zijn dan degenen die ongevaccineerd blijven, meldt RAIR.

Het aantal Amerikanen dat ernstige bijwerkingen heeft gekregen of is overleden na het krijgen van de mRNA-injectie die als "vaccin" wordt aangekondigd, stijgt explosief. Bovendien lijken geïnjecteerde mensen veel slechter af te zijn dan degenen die de experimentele prik weigeren. Maar ondanks het feit dat het "vaccin" en de "boosters" mensen niet beschermen tegen Covid en de kans op besmetting met

Omicron vergroten, blijven regeringen wereldwijd burgers onder druk zetten en verplichten om ze te krijgen.

Angstaanjagende 'Vaccin' bijwerkingen

One American News (OAN) meldt dat vanaf 4 januari 2022, negenhonderd zesenvestigduizend Amerikanen ernstige bijwerkingen hebben ondervonden of zijn overleden na te zijn geïnjecteerd. Daarnaast stelt het Amerikaanse ministerie van Volksgezondheid dat meer dan 100.000 Amerikanen in het ziekenhuis zijn opgenomen na het krijgen van de prik.

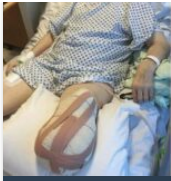Degenen die lijden aan de bijwerkingen van de injectie zijn niet alleen naamloze figuren op een pagina, meldt OAN.

[Angelia Desselle](#) uit Louisiana kon bijvoorbeeld nauwelijks staan na haar prik en lijdt aan een neurologische aandoening die volgens artsen het gevolg is van het vaccin. Evenzo is Shawn Skelton uit Indiana verzwakt en heeft zij de controle over haar lichaam verloren sinds de Pfizer-prik.

De volledig "gevaccineerde" Jummai Nache uit Minnesota moest na de vaccinatie haar benen en handen amputeren. De 13-jarige Maddie de Garay uit Ohio is vanaf haar middel verlamd, krijgt sondevoeding en heeft de volledige controle over haar lichaamsfuncties verloren.

Gezondheidsfunctionarissen in [Vietnam](#) hebben het gebruik van het Pfizer-vaccin opgeschort nadat meer dan 120 kinderen in het ziekenhuis waren opgenomen vanwege ernstige reacties op de injecties. In een ander nabijgelegen district zijn zelfs drie kinderen overleden.





Een lijst van mensen bij wie hun been werd geamputeerd kort na de vaccinspuit

Veiliger om niet gevaccineerd te worden?

Volgens het Vaccine Adverse Event Reporting System (VAERS) en de U.S. Centers for Disease Control and Prevention (CDC) zijn er iets meer dan 20.000 sterfgevallen na de injecties.

Onderzoekers van Columbia University [melden](#) echter dat het werkelijke aantal mensen dat is overleden als gevolg van het krijgen van een van de experimentele injecties aanzienlijk hoger ligt dan de officiële cijfers. Columbia University schat dat de onderrapportagefactor 20 keer dat aantal, of ongeveer 400.000 sterfgevallen, veel nauwkeuriger is.

Bovendien rapporteert Alex Berenson, voormalig verslaggever van de New York Times, dat de mRNA-injecties nu [een sterk negatieve uitwerking](#) hebben. De injecties verhogen in feite de kans op besmetting door Omicron.

Stervende kinderen

Volgens OAN zijn ook tienduizenden mensen, waaronder kinderen, overleden na de inenting. De dertienjarige [Jacob Clynick](#) uit Michigan overleed in zijn slaap kort nadat hij zijn tweede Pfizer-prik had gekregen. Een 11-jarig meisje uit Georgia overleed kort na haar Pfizer-vaccin. Ook overleed een 5-jarig meisje vier dagen nadat ze haar eerste Pfizer-prik had gekregen. Bovendien kreeg een 8-jarig meisje een

beroerte en een hersenbloeding zeven dagen na de Pfizer-prik.

"We zien nu de gevolgen van dit ongeteste, onbewezen en inderhaast ontwikkelde vaccin, en het is veel erger dan we vreesden," zei Pearson Sharp van de OAN, "en dit is nog maar het begin." Hij vervolgde: "Tenzij Amerikanen en ouders in opstand komen tegen deze onwetenschappelijke mandaten, kunnen we nog honderdduizenden doden en permanent gewonde slachtoffers verwachten van het grootste experiment op mensen in de geschiedenis."

Bekijk een recente reportage van One America News:

Help ons de censuur van BIG-TECH te omzeilen en volg ons op Telegram:

Telegram: t.me/dissidenteent

Meld je aan voor onze gratis dagelijkse nieuwsbrief, 10.000 gingen je al voor:

DissidentNL

Als ze je kunnen verplichten een vaccin te nemen, kunnen ze je ook verplichten je te laten steriliseren, euthanasie te plegen of op verzoek een orgaan af te staan. Als je lichamelijke integriteit geschonden kan worden door de overheid dan kunnen ze alles met je doen. Dan ben je feitelijk een slaaf.

De hersenen van 'gevaccineerde mensen' lopen groot gevaar.

zaterdag, 29 april 2023 11:27 Hits: 3154



Wat men probeert te doen met de beruchte 'coronavaccin' is dat lichaam zelf het gevaarlijkste deel van het virus gaat produceren (spike eitwitten).

Als nu uit nieuw onderzoek blijkt dat dit virus bij mensen die geïnfecteerd zijn geweest de hersenen doet krimpen, wat doen de 'vaccinaties' dan met diezelfde hersenen?

Voor de leesbaarheid gaan we er in dit artikel vanuit dat virussen bestaan en dat er inderdaad spike eiwitten worden aangemaakt door de 'corona vaccins'.

Er is een levensgroot verschil tussen klassieke vaccinaties en de beruchte mRNA 'vaccins' zoals die zijn gebruikt ten tijde van corona.

Bij klassieke vaccins wordt een beetje al dan niet levend virusmateriaal ingespoten waardoor dit bij het lichaam een afweerreactie oproept. De theorie is dan dat een volgende keer als iemand met het echte virus in aanraking komt, het immuunsysteem dit zal herkennen als een indringer.

Bij mRNA vaccinaties wordt een heel ander principe gehanteerd.

(<https://www.google.com/search?client=opera&q=hoe+werkt+een+mRNA+vaccin&sourceid=opera&ie=UTF-8&oe=UTF-8>)

Het brengt hele kleine vetbolletjes in het lichaam met een stukje genetische code (mRNA). Dit is dezelfde code die ook aanwezig is in het coronavirus. Dit mRNA wordt in het lichaam omgezet in spikeproteïnen, een eiwit van het virus.

Nu blijkt uit onderzoek dat bij mensen die een zogenaamde covid-19 infectie hebben doorgemaakt dit een negatief effect heeft op de hersenen.

(<https://www.gezondheidsnet.nl/coronavirus/onderzoekers-brein-kan-krimpen-na-corona-infectie>)

Na het doormaken van een besmetting met het coronavirus is bij patiënten vijf maanden na de infectie schade aan het brein te zien. Ook bij mensen die een milde infectie hadden.

Britse onderzoekers ontdekten dit toen ze hersenscans van voor en na de infectie met elkaar vergeleken van zo'n 800 deelnemers in een Britse biobank.

Ook bleek het brein als geheel wat gekrompen. En zijn bepaalde cognitieve vermogens sterker afgenomen bij mensen die de Covid-19 hebben doorgemaakt, vergeleken met niet-besmette mensen.

Laten we er even vanuit gaan dat het verhaal klopt en dat mensen die een infectie hebben doorgemaakt inderdaad te maken krijgen met bovengenoemde verschijnselen.

Maar, hoe zit het dan met de hersenen van 'gevaccineerde mensen'? Dit omdat via de mRNA de cellen opdracht krijgen om misschien wel miljarden van die spike eiwitten aan te maken.

Volgens wetenschappers blijven deze niet op één plek in het lichaam, maar zwerven door het gehele lichaam en komen ook in de hersenen terecht.

In het licht van bovenstaande is het heel goed om te kijken wat de bekende Dr. Sucharit Bhakdi had te vertellen over spike eiwitten en hersenen.

Dan zie je dat hetgeen de wetenschappers nu hebben ontdekt niets anders is dan een verregaande vorm van vaccinatieschade, de zoveelste.

Hieronder staat een interview dat Greg Hunter had met Dr. Sucharit Bhakdi. De man, die al heel lang waarschuwt tegen de grote gevaren van de experimentele gentherapie, in de volksmond 'coronavaccin' genoemd.

In onderstaand interview claimt hij dat wanneer onderdelen (spike eiwitten) van het 'vaccin' erin slagen om het hart of de hersenen te bereiken, daar dusdanige schade veroorzaakt gaat worden dat deze niet meer gerepareerd kan worden.

Hij baseert zich daarbij op een lijkschouwing waaruit dit duidelijk werd. Want, in meerdere delen van de hersenen kwam de arts die de lijkschouwing uitvoerde hetzelfde verschijnselen tegen. Hij ontdekte dat de beruchte spike eiwitten waren doorgedrongen tot de allerkleinste bloedvaten in de hersenen.

Dit bleek fataal, want het immuunsysteem ging deze kleine bloedvaten aanvallen en vernietigde deze. Hierdoor is er geen enkele reparatie meer mogelijk.

De arts die de lijkschouwing uitvoerde vond onweerlegbaar bewijs dat de cellen in de hersenen of dood waren of bezig te sterven.

De patiënt in kwestie had op meerdere locaties in het lichaam last van dit verschijnsel. Cellen die bezig waren met afsterven of al gestorven waren.

Wat er gebeurt met mensen bij wie de spike eiwitten doordringen tot in de hersenen is dat ze hun persoonlijkheid verliezen, aldus Bhakdi (<https://lionessofjudah.substack.com/p/cv19-vax-destroys-hearts-and-brains>). Ze worden letterlijk gek. Ze kunnen niet langer nadenken, ze worden dement. Ze kunnen niet meer horen en/of ze kunnen niet meer zien. Ze kunnen niet meer spreken.

Zij zijn niet langer de mensen die ze ooit waren. Zij zijn verwoeste menselijke wezens. Hun hersenen zijn vernietigd.

Naast dit soort afgrijselijke verschijnselen met de hersenen, gebeurt er iets vergelijkbaar met het hart als de spike eiwitten daar weten door te dringen. Bij de lijkschouwing kwam de arts ook daar de spike eiwitten tegen.

Dit betekent dat via de experimentele gentherapie bij miljarden mensen dezelfde dood en verderf zaaiende spike eiwitten zullen worden aangetroffen. Dat ook bij die mensen het hart en de hersenen bereikt zullen worden.

Volgens Dr. Bhakdi sterven deze mensen een vreselijke dood.

Hij concludeert aan het eind:

Ik moet helaas toegeven dat tot ongeveer anderhalf jaar geleden ik een wetenschapper was. Nu zie ik wat er werkelijk gebeurt. Ik moet bekennen dat collega's en vrienden die mij vertellen dat dit een genocide is, gelijk hebben.

Ik weet het niet, maar er kan simpelweg geen andere agenda zijn. Er is geen andere verklaring.

Er is geen andere verklaring omdat we niet te maken hebben met een 'killervirus' waaraan iedereen aan dood gaat.

Iemand die dat wel durft te beweren staat ons keihard voor te liegen.

Deze zogenaamde 'vaccins' zouden nooit in staat zijn geweest om ons te beschermen tegen infecties.

En in de laatste plaats zijn deze genterapie 'vaccins' de meest vreselijke instrumenten die ooit zijn ingebracht in het menselijk lichaam met als doel om deze te verwoesten.

Deze 'vaccins' zullen de mensheid uitroeien.



Bezoek ook eens gezondheidswebwinkel Orjana.nl (<https://Orjana.nl>)

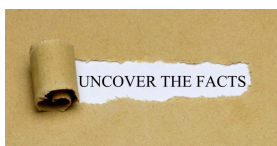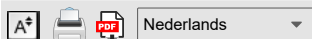
COVID-19-vaccins: bewijs van dodelijkheid. Meer dan duizend wetenschappelijke studies

Door [ZON](#)

Wereldwijd onderzoek, 15 april 2023
ZO 5 januari 2022

Regio: Europa

Thema: Media Desinformatie , Wetenschap en Geneeskunde



Alle Global Research-artikelen kunnen in 51 talen worden gelezen door het vervolgkeuzemenu "Website vertalen" te activeren op de bovenste banner van onze startpagina (desktopversie).

Klik [hier](#) om de dagelijkse nieuwsbrief van Global Research (geselecteerde artikelen) te ontvangen .

Bezoek en volg ons op Instagram op [@globalresearch_crg](#) .

Voor het eerst gepubliceerd door Global Research op 21 januari 2022

Sinds de publicatie van dit artikel is het aantal onderzoeken toegenomen. Het bewijs is overweldigend.

Meer dan duizend wetenschappelijke studies bewijzen dat de COVID-19-vaccins gevaarlijk zijn, en dat iedereen die deze agenda nastreeft, de strafbare misdaad van grof wangedrag in een openbaar ambt begaat

lets meer dan 12 maanden na de inzet van de COVID 19-noodexperimentele vaccins, duizenden wetenschappelijke studies en meldingen van mishandeling en moord door het illegale, onwettige gebruik van biochemische gifstoffen bij politiediensten in het hele land, verifieer een aanval op een nietsvermoedende Britse bevolking. Onweerlegbare wetenschap toont aan dat het COVID 19-vaccin niet veilig en niet effectief is in het beperken van de overdracht of infectie van de SARS-CoV-2, coronaviruspathogenen.

De "veilige en effectieve" valse propaganda, verspreid door overheidsfunctionarissen die dit vaccin nu blijven pushen, is een duidelijke plichtsverzuim. Een openbaar ambtsdrager is onderworpen aan en is zich bewust van de plicht om overlijden of ernstig letsel te voorkomen dat alleen ontstaat uit hoofde van de functies van het openbaar ambt.

Velen hebben die plicht geschonden en veroorzaken daardoor roekeloos een risico op overlijden of ernstig letsel, door door te gaan ondanks de nu bevestigde gevaren die gepaard gaan met COVID 19-injecties. Sommige van deze risico's zijn **bloedstolling, myocarditis, pericarditis, trombose, trombocytopenie, anafylaxie, Bell's palsy, Guillain-Barre, kanker inclusief sterfgevallen**, enz .

Dit alles wordt bevestigd in de volgende door **de wetenschap en de overheid verzamelde gegevens van de Britse gezondheids- en veiligheidsdienst over COVID 19 met betrekking tot vaccinschade.**

De term "vaccin" is onlangs gewijzigd om dit illegale, onwettige medische experiment op te nemen om het gebruik van mRNA-technologie te vergemakkelijken die aantoonbaar geen vaccin is en die biologisch giftige nano-metamaterialen bevat die verband houden met de 5G-capaciteit voor het verzamelen van stedelijke gegevens.

In de wetenschap is bekend dat nanodeeltjes van metaal genotoxisch zijn – een gif dat ook sterilisatie kan veroorzaken. De gevaren voor de slachtoffers op korte termijn van deze medische batterij zijn nu bekend. De dodelijkheid van dit wapen op lange termijn wordt echter nog niet gerealiseerd vanwege de slopende effecten die het heeft op het immuunsysteem, waardoor het Acquired Immunodeficiency Syndrome (AIDS) ontstaat.

De Medicines and Healthcare (products) Regulatory Agency (MHRA) had voorafgaande waarschuwing van de verwachte grote aantallen bijwerkingen vóór de inzet, wat de met voorbedachten rade aard van de misdaad en openbare gedragsdelicten toen en nu bevestigde.

1. Cerebrale veneuze trombose na COVID-19-vaccinatie in het VK: een multicenter cohortonderzoek: [https://www.thelancet.com/journals/lancet/article/PIIS0140-6736\(21\)01608-1](https://www.thelancet.com/journals/lancet/article/PIIS0140-6736(21)01608-1)
2. Vaccin-geïnduceerde immuuntrombotische trombocytopenie met gedissemineerde intravasculaire stolling en overlijden na ChAdOx1 nCoV-19-vaccinatie: <https://www.sciencedirect.com/science/article/pii/S1052305721003414>
3. Fatale hersenbloeding na COVID-19-vaccin: <https://pubmed.ncbi.nlm.nih.gov/33928772/>
4. Myocarditis na mRNA-vaccinatie tegen SARS-CoV-2, een casusreeks: <https://www.sciencedirect.com/science/article/pii/S2666602221000409>
5. Drie gevallen van acute veneuze trombo-embolie bij vrouwen na vaccinatie tegen COVID-19: <https://www.sciencedirect.com/science/article/pii/S2213333X21003929>

6. Acute trombose van de kroonboom na vaccinatie tegen COVID-19: <https://www.sciencedirect.com/science/article/abs/pii/S1936879821003988>
7. Amerikaanse casusrapporten van cerebrale veneuze sinustrombose met trombocytopenie na vaccinatie met Ad26.COV2.S (tegen covid-19), 2 maart tot 21 april 2020: <https://pubmed.ncbi.nlm.nih.gov/33929487/>
8. Trombose van de poortader geassocieerd met ChAdOx1 nCov-19-vaccin: [https://www.thelancet.com/journals/langas/article/PIIS2468-1253\(21\)00197-7/](https://www.thelancet.com/journals/langas/article/PIIS2468-1253(21)00197-7/)
9. Beheer van cerebrale en splanchnische veneuze trombose geassocieerd met trombocytopenie bij proefpersonen die eerder zijn gevaccineerd met Vaxzevria (AstraZeneca): standpuntbepaling van de Italiaanse Vereniging voor de Studie van Hemostase en Trombose (SISST): <https://pubmed.ncbi.nlm.nih.gov/33871350/>
10. Vaccin-geïnduceerde immuun-immune trombotische trombocytopenie en cerebrale veneuze sinustrombose na vaccinatie met COVID-19; een systematische review: <https://www.sciencedirect.com/science/article/pii/S0022510X21003014>
11. Trombose met trombocytopeniesyndroom geassocieerd met COVID-19-vaccins: <https://www.sciencedirect.com/science/article/abs/pii/S0735675721004381>
12. Door covid-19 vaccin veroorzaakte trombose en trombocytopenie: een commentaar op een belangrijk en praktisch klinisch dilemma: <https://www.sciencedirect.com/science/article/abs/pii/S0033062021000505>
13. Trombose met trombocytopeniesyndroom geassocieerd met COVID-19 virale vectorvaccins: <https://www.sciencedirect.com/science/article/abs/pii/S0953620521001904>
14. COVID-19 vaccin-geïnduceerde immuun-immune trombotische trombocytopenie: een opkomende oorzaak van splanchnische veneuze trombose: <https://www.sciencedirect.com/science/article/pii/S1665268121000557>
15. De rol van bloedplaatjes bij COVID-19-geassocieerde coagulopathie en vaccin-geïnduceerde immuuntrombotische immuuntrombocytopenie (covid): <https://www.sciencedirect.com/science/article/pii/S1050173821000967>
16. Oorzaken van auto-immuniteit van trombotische gebeurtenissen na COVID-19-vaccinatie: <https://www.sciencedirect.com/science/article/abs/pii/S1568997221002160>
17. Cerebrale veneuze sinustrombose na vaccinatie: ervaring in het Verenigd Koninkrijk: [https://www.thelancet.com/journals/lancet/article/PIIS0140-6736\(21\)01788-8/fulltext](https://www.thelancet.com/journals/lancet/article/PIIS0140-6736(21)01788-8/fulltext)
18. Trombotische immuuntrombocytopenie geïnduceerd door SARS-CoV-2-vaccin: <https://www.nejm.org/doi/full/10.1056/nejme2106315>
19. Myocarditis na immunisatie met COVID-19 mRNA-vaccins bij leden van het Amerikaanse leger. Dit artikel meldt dat bij "23 mannelijke patiënten, waaronder 22 voorheen gezonde militairen, myocarditis werd vastgesteld binnen 4 dagen na ontvangst van het vaccin": <https://jamanetwork.com/journals/jamacardiology/fullarticle/2781601>
20. Trombose en trombocytopenie na vaccinatie met ChAdOx1 nCoV-19: https://www.nejm.org/doi/full/10.1056/NEJMoa2104882?query=recirc_curatedRelated_article
21. Associatie van myocarditis met het BNT162b2 messenger RNA COVID-19-vaccin in een casusreeks van kinderen: <https://pubmed.ncbi.nlm.nih.gov/34374740/>
22. Trombotische trombocytopenie na vaccinatie met ChAdOx1 nCoV-19: https://www.nejm.org/doi/full/10.1056/NEJMoa2104840?query=recirc_curatedRelated_article
23. Post-mortem bevindingen bij vaccin-geïnduceerde trombotische trombocytopenie (covid-19): <https://haematologica.org/article/view/haematol.2021.279075>
24. Trombocytopenie, inclusief immuuntrombocytopenie na ontvangst van COVID-19-mRNA-vaccins gemeld aan het Vaccine Adverse Event Reporting System (VAERS): <https://www.sciencedirect.com/science/article/pii/S0264410X21005247>
25. Acute symptomatische myocarditis bij zeven adolescenten na Pfizer-BioNTech COVID-19-vaccinatie: <https://pediatrics.aappublications.org/content/early/2021/06/04/peds.2021-052478>
26. Aphasia seven days after the second dose of an mRNA-based SARS-CoV-2 vaccine. Brain MRI revealed an intracerebral hemorrhage (ICBH) in the left temporal lobe in a 52-year-old man. <https://www.sciencedirect.com/science/article/pii/S2589238X21000292#f0005>
27. Comparison of vaccine-induced thrombotic episodes between ChAdOx1 nCoV-19 and Ad26.COV.2.S vaccines: <https://www.sciencedirect.com/science/article/abs/pii/S0896841121000895>
28. Hypothesis behind the very rare cases of thrombosis with thrombocytopenia syndrome after SARS-CoV-2 vaccination: <https://www.sciencedirect.com/science/article/abs/pii/S0049384821003315>
29. Blood clots and bleeding episodes after BNT162b2 and ChAdOx1 nCoV-19 vaccination: analysis of European data: <https://www.sciencedirect.com/science/article/pii/S0896841121000937>
30. Cerebral venous thrombosis after BNT162b2 mRNA SARS-CoV-2 vaccine: <https://www.sciencedirect.com/science/article/abs/pii/S1052305721003098>
31. Primary adrenal insufficiency associated with thrombotic immune thrombocytopenia induced by the Oxford-AstraZeneca ChAdOx1 nCoV-19 vaccine (VITT): <https://www.sciencedirect.com/science/article/pii/S0953620521002363>
32. Myocarditis and pericarditis after vaccination with COVID-19 mRNA: practical considerations for care providers: <https://www.sciencedirect.com/science/article/pii/S0828282X21006243>
33. "Portal vein thrombosis occurring after the first dose of SARS-CoV-2 mRNA vaccine in a patient with antiphospholipid syndrome": <https://www.sciencedirect.com/science/article/pii/S2666572721000389>
34. Early results of bivalirudin treatment for thrombotic thrombocytopenia and cerebral venous sinus thrombosis after vaccination with Ad26.COV2.S: <https://www.sciencedirect.com/science/article/pii/S0196064421003425>
35. Myocarditis, pericarditis and cardiomyopathy after COVID-19 vaccination: <https://www.sciencedirect.com/science/article/pii/S1443950621011562>
36. Mechanisms of immunothrombosis in vaccine-induced thrombotic thrombocytopenia (VITT) compared to natural SARS-CoV-2 infection: <https://www.sciencedirect.com/science/article/abs/pii/S0896841121000706>
37. Prothrombotic immune thrombocytopenia after COVID-19 vaccination: <https://www.sciencedirect.com/science/article/pii/S0006497121009411>
38. Vaccine-induced thrombotic thrombocytopenia: the dark chapter of a success story: <https://www.sciencedirect.com/science/article/pii/S2589936821000256>
39. Cerebral venous sinus thrombosis negative for anti-PF4 antibody without thrombocytopenia after immunization with COVID-19 vaccine in a non-comorbid elderly Indian male treated with conventional heparin-warfarin based anticoagulation: <https://www.sciencedirect.com/science/article/pii/S1871402121002046>

40. Thrombosis after COVID-19 vaccination: possible link to ACE pathways: <https://www.sciencedirect.com/science/article/pii/S0049384821004369>
41. Cerebral venous sinus thrombosis in the U.S. population after SARS-CoV-2 vaccination with adenovirus and after COVID-19: <https://www.sciencedirect.com/science/article/pii/S0735109721051949>
42. A rare case of a middle-aged Asian male with cerebral venous thrombosis after AstraZeneca COVID-19 vaccination: <https://www.sciencedirect.com/science/article/pii/S0735675721005714>
43. Cerebral venous sinus thrombosis and thrombocytopenia after COVID-19 vaccination: report of two cases in the United Kingdom: <https://www.sciencedirect.com/science/article/abs/pii/S088915912100163X>
44. Immune thrombocytopenic purpura after vaccination with COVID-19 vaccine (ChAdOx1 nCov-19): <https://www.sciencedirect.com/science/article/abs/pii/S0006497121013963>.
45. Antiphospholipid antibodies and risk of thrombophilia after COVID-19 vaccination: the straw that breaks the camel's back?: <https://docs.google.com/document/d/1XzajasO8VMMn3CdxSBKks1o7kiOLXFQ>
46. Vaccine-induced thrombotic thrombocytopenia, a rare but severe case of friendly fire in the battle against the COVID-19 pandemic: What pathogenesis?: <https://www.sciencedirect.com/science/article/pii/S0953620521002314>
47. Diagnostic-therapeutic recommendations of the ad-hoc FACME expert working group on the management of cerebral venous thrombosis related to COVID-19 vaccination: <https://www.sciencedirect.com/science/article/pii/S0213485321000839>
48. Trombocytopenie en intracraniale veneuze sinus trombose na blootstelling aan het "AstraZeneca COVID-19-vaccin": <https://pubmed.ncbi.nlm.nih.gov/33918932/>
49. Trombocytopenie na Pfizer en Moderna SARS-CoV-2-vaccinatie: <https://pubmed.ncbi.nlm.nih.gov/33606296/>
50. Ernstige en refractaire immuuntrombocytopenie die optreedt na SARS-CoV-2-vaccinatie: <https://pubmed.ncbi.nlm.nih.gov/33854395/>
51. Purpurische huiduitslag en trombocytopenie na mRNA-1273 (modern) COVID-19-vaccin: <https://www.ncbi.nlm.nih.gov/pmc/articles/PMC7996471/>
52. COVID-19-vaccinatie: informatie over het optreden van arteriële en veneuze trombose aan de hand van gegevens uit VigiBase: <https://pubmed.ncbi.nlm.nih.gov/33863748/>
53. Cerebrale veneuze trombose geassocieerd met het covid-19-vaccin in Duitsland: <https://onlinelibrary.wiley.com/doi/10.1002/ana.26172>
54. Cerebrale veneuze trombose na BNT162b2-mRNA-vaccinatie van BNT162b2 tegen SARS-CoV-2: een zwarte-zwaangebeurtenis: <https://pubmed.ncbi.nlm.nih.gov/34133027/>
55. Het belang van het herkennen van cerebrale veneuze trombose na anti-COVID-19 vaccinatie: <https://pubmed.ncbi.nlm.nih.gov/34001390/>
56. Trombose met trombocytopenie na messenger RNA-vaccin -1273: <https://pubmed.ncbi.nlm.nih.gov/34181446/>
57. Bloedstolsels en bloedingen na vaccinatie tegen BNT162b2 en ChAdOx1 nCov-19: een analyse van Europese gegevens: <https://pubmed.ncbi.nlm.nih.gov/34174723/>
58. Eerste dosis ChAdOx1 en BNT162b2 COVID-19-vaccins en trombocytopenische, trombo-embolische en hemorragische gebeurtenissen in Schotland: <https://www.nature.com/articles/s41591-021-01408-4>
59. Verergering van immuuntrombocytopenie na COVID-19-vaccinatie: <https://pubmed.ncbi.nlm.nih.gov/34075578/>
60. Eerste melding van een de novo iTTP-episode geassocieerd met een op COVID-19 mRNA gebaseerd anti-COVID-19-vaccin: <https://pubmed.ncbi.nlm.nih.gov/34105244/>
61. PF4-immunoassays bij vaccin-geïnduceerde trombotische trombocytopenie: <https://www.nejm.org/doi/full/10.1056/NEJM2106383>
62. Antilichaam-epitopen bij vaccin-geïnduceerde immuun-immune trombotische trombocytopenie: <https://www.nature.com/articles/s41586-021-03744-4>
63. Myocarditis met COVID-19 mRNA-vaccins: <https://www.ahajournals.org/doi/pdf/10.1161/CIRCULATIONAHA.121.056135>
64. Myocarditis en pericarditis na COVID-19-vaccinatie: <https://jamanetwork.com/journals/jama/fullarticle/2782900>
65. Myocarditis tijdelijk geassocieerd met COVID-19-vaccinatie: <https://www.ahajournals.org/doi/pdf/10.1161/CIRCULATIONAHA.121.055891>
66. COVID-19-vaccinatie geassocieerd met myocarditis bij adolescenten: <https://pediatrics.aappublications.org/content/pediatrics/early/2021/08/12/peds.2021-053427.full.pdf>
67. Acute myocarditis na toediening van BNT162b2-vaccin tegen COVID-19: <https://pubmed.ncbi.nlm.nih.gov/33994339/>
68. Tijdelijk verband tussen COVID-19-vaccin Ad26.COV2.S en acute myocarditis: casusrapport en literatuuroverzicht: <https://www.sciencedirect.com/science/article/pii/S1553838921005789>
69. COVID-19 vaccin-geïnduceerde myocarditis: een casusrapport met literatuuroverzicht: <https://www.sciencedirect.com/science/article/pii/S1871402121002253>
70. Mogelijk verband tussen COVID-19-vaccin en myocarditis: klinische en CMR-bevindingen: <https://www.sciencedirect.com/science/article/pii/S1936878X2100485X>
71. Herhaling van acute myocarditis tijdelijk geassocieerd met ontvangst van coronavirus mRNA-ziektevaccin 2019 (COVID-19) bij een mannelijke adolescent: <https://www.sciencedirect.com/science/article/pii/S002234762100617X>
72. Fulminante myocarditis en systemische hyperontsteking tijdelijk geassocieerd met BNT162b2 COVID-19 mRNA-vaccinatie bij twee patiënten: <https://www.sciencedirect.com/science/article/pii/S0167527321012286>
73. Acute myocarditis na toediening van het BNT162b2-vaccin: <https://www.sciencedirect.com/science/article/pii/S2214250921001530>
74. Lymfocytische myocarditis na vaccinatie met COVID-19 Ad26.COV2.S virale vector: <https://www.sciencedirect.com/science/article/pii/S2352906721001573>
75. Myocarditis na vaccinatie met BNT162b2 bij een gezonde man: <https://www.sciencedirect.com/science/article/pii/S0735675721005362>
76. Acute myocarditis na Comirnaty (Pfizer)-vaccinatie bij een gezonde man met eerdere SARS-CoV-2-infectie: <https://www.sciencedirect.com/science/article/pii/S1930043321005549>
77. Myopericarditis na Pfizer mRNA COVID-19-vaccinatie bij adolescenten: <https://www.sciencedirect.com/science/article/pii/S002234762100666X>
78. Pericarditis na toediening van BNT162b2 mRNA COVID-19 mRNA-vaccin: <https://www.sciencedirect.com/science/article/pii/S1885585721002218>
79. Acute myocarditis na vaccinatie met SARS-CoV-2 mRNA-1273 mRNA: <https://www.sciencedirect.com/science/article/pii/S2589790X21001931>
80. Tijdelijke relatie tussen de tweede dosis van het BNT162b2-mRNA Covid-19-vaccin en cardiale betrokkenheid bij een patiënt met eerdere SARS-COV-2-infectie: <https://www.sciencedirect.com/science/article/pii/S2352906721000622>
81. Myopericarditis na vaccinatie met COVID-19 mRNA bij adolescenten van 12 tot 18 jaar: <https://www.sciencedirect.com/science/article>

- /pii/S0022347621007368
82. Acute myocarditis na SARS-CoV-2-vaccinatie bij een 24-jarige man: <https://www.sciencedirect.com/science/article/pii/S0870255121003243>
 83. Belangrijke informatie over myopericarditis na vaccinatie met Pfizer COVID-19 mRNA bij adolescenten: <https://www.sciencedirect.com/science/article/pii/S0022347621007496>
 84. Een reeks patiënten met myocarditis na vaccinatie tegen SARS-CoV-2 met mRNA-1279 en BNT162b2: <https://www.sciencedirect.com/science/article/pii/S1936878X21004861>
 85. Takotsubo-cardiomyopathie na vaccinatie met mRNA COVID-19: <https://www.sciencedirect.com/science/article/pii/S1443950621011331>
 86. COVID-19 mRNA-vaccinatie en myocarditis: <https://pubmed.ncbi.nlm.nih.gov/34268277/>
 87. COVID-19-vaccin en myocarditis: <https://pubmed.ncbi.nlm.nih.gov/34399967/>
 88. Epidemiologie en klinische kenmerken van myocarditis/pericarditis vóór de introductie van het COVID-19 mRNA-vaccin bij Koreaanse kinderen: een multicenter onderzoek <https://search.bvsalud.org/global-literature-on-novel-coronavirus-2019-ncov/resource/nl/covidwho-1360706>
 89. COVID-19 vaccines and myocarditis: <https://pubmed.ncbi.nlm.nih.gov/34246566/>
 90. Myocarditis and other cardiovascular complications of COVID-19 mRNA-based COVID-19 vaccines <https://www.cureus.com/articles/61030-myocarditis-and-other-cardiovascular-complications-of-the-mrna-based-covid-19-vaccines> <https://www.cureus.com/articles/61030-myocarditis-and-other-cardiovascular-complications-of-the-mrna-based-covid-19-vaccines>
 91. Myocarditis, pericarditis, and cardiomyopathy after COVID-19 vaccination: <https://pubmed.ncbi.nlm.nih.gov/34340927/>
 92. Myocarditis with covid-19 mRNA vaccines: <https://www.ahajournals.org/doi/10.1161/CIRCULATIONAHA.121.056135>
 93. Association of myocarditis with COVID-19 mRNA vaccine in children: <https://media.jamanetwork.com/news-item/association-of-myocarditis-with-mrna-covid-19-vaccine-in-children/>
 94. Association of myocarditis with COVID-19 messenger RNA vaccine BNT162b2 in a case series of children: <https://jamanetwork.com/journals/jamacardiology/fullarticle/2783052>
 95. Myocarditis after immunization with COVID-19 mRNA vaccines in members of the U.S. military: <https://jamanetwork.com/journals/jamacardiology/fullarticle/2781601%5C>
 96. Myocarditis occurring after immunization with COVID-19 mRNA-based COVID-19 vaccines: <https://jamanetwork.com/journals/jamacardiology/fullarticle/2781600>
 97. Myocarditis following immunization with Covid-19 mRNA: <https://www.nejm.org/doi/full/10.1056/NEJMc2109975>
 98. Patients with acute myocarditis after vaccination with COVID-19 mRNA: <https://jamanetwork.com/journals/jamacardiology/fullarticle/2781602>
 99. Myocarditis associated with vaccination with COVID-19 mRNA: <https://pubs.rsna.org/doi/10.1148/radiol.2021211430>
 100. Symptomatic Acute Myocarditis in 7 Adolescents after Pfizer-BioNTech COVID-19 Vaccination: <https://pediatrics.aappublications.org/content/148/3/e2021052478>
 101. Cardiovascular magnetic resonance imaging findings in young adult patients with acute myocarditis after COVID-19 mRNA vaccination: a case series: <https://jcmr-online.biomedcentral.com/articles/10.1186/s12968-021-00795-4>
 102. Clinical Guidance for Young People with Myocarditis and Pericarditis after Vaccination with COVID-19 mRNA: <https://www.cps.ca/en/documents/position/clinical-guidance-for-youth-with-myocarditis-and-pericarditis>
 103. Cardiac imaging of acute myocarditis after vaccination with COVID-19 mRNA: <https://pubmed.ncbi.nlm.nih.gov/34402228/>
 104. Case report: acute myocarditis after second dose of mRNA-1273 SARS-CoV-2 mRNA vaccine: <https://academic.oup.com/ehjcr/article/5/8/ytab319/6339567>
 105. Myocarditis / pericarditis associated with COVID-19 vaccine: https://science.gc.ca/eic/site/063.nsf/eng/h_98291.html
 106. Transient cardiac injury in adolescents receiving the BNT162b2 mRNA COVID-19 vaccine: https://journals.lww.com/pidj/Abstract/9000/Transient_Cardiac_Injury_in_Adolescents_Receiving.95800.aspx
 107. Perimyocarditis in adolescents after Pfizer-BioNTech COVID-19 vaccine: <https://academic.oup.com/jpids/advance-article/doi/10.1093/jpids/piab060/6329543>
 108. The new COVID-19 mRNA vaccine platform and myocarditis: clues to the possible underlying mechanism: <https://pubmed.ncbi.nlm.nih.gov/34312010/>
 109. Acute myocardial injury after COVID-19 vaccination: a case report and review of current evidence from the Vaccine Adverse Event Reporting System database: <https://pubmed.ncbi.nlm.nih.gov/34219532/>
 110. Be alert to the risk of adverse cardiovascular events after COVID-19 vaccination: <https://www.xiahepublishing.com/m/2472-0712/ERHM-2021-00033>
 111. Myocarditis associated with COVID-19 vaccination: echocardiographic, cardiac tomography, and magnetic resonance imaging findings: <https://www.ahajournals.org/doi/10.1161/CIRCIMAGING.121.013236>
 112. In-depth evaluation of a case of presumed myocarditis after the second dose of COVID-19 mRNA vaccine: <https://www.ahajournals.org/doi/10.1161/CIRCULATIONAHA.121.056038>
 113. Occurrence of acute infarct-like myocarditis after COVID-19 vaccination: just an accidental coincidence or rather a vaccination-associated autoimmune myocarditis?: <https://pubmed.ncbi.nlm.nih.gov/34333695/>
 114. Recurrence of acute myocarditis temporally associated with receipt of coronavirus mRNA disease vaccine 2019 (COVID-19) in a male adolescent: <https://www.ncbi.nlm.nih.gov/pmc/articles/PMC8216855/>
 115. Myocarditis after SARS-CoV-2 vaccination: a vaccine-induced reaction?: <https://pubmed.ncbi.nlm.nih.gov/34118375/>
 116. Self-limited myocarditis presenting with chest pain and ST-segment elevation in adolescents after vaccination with the BNT162b2 mRNA vaccine: <https://pubmed.ncbi.nlm.nih.gov/34180390/>
 117. Myopericarditis in a previously healthy adolescent male after COVID-19 vaccination: Case report: <https://pubmed.ncbi.nlm.nih.gov/34133825/>
 118. Biopsy-proven lymphocytic myocarditis after first COVID-19 mRNA vaccination in a 40-year-old man: case report: <https://pubmed.ncbi.nlm.nih.gov/34487236/>
 119. Insights from a murine model of COVID-19 mRNA vaccine-induced myopericarditis: could accidental intravenous injection of a vaccine induce myopericarditis <https://academic.oup.com/cid/advance-article/doi/10.1093/cid/ciab741/6359059>
 120. Unusual presentation of acute perimyocarditis after modern SARS-COV-2 mRNA-1237 vaccination: <https://pubmed.ncbi.nlm.nih.gov/34447639/>
 121. Perimyocarditis after the first dose of mRNA-1273 SARS-CoV-2 (Modern) mRNA-1273 vaccine in a young healthy male: case report: <https://bmccardiovascdisord.biomedcentral.com/articles/10.1186/s12872-021-02183>

122. Acute myocarditis after the second dose of SARS-CoV-2 vaccine: serendipity or causal relationship: <https://pubmed.ncbi.nlm.nih.gov/34236331/>
123. Rhabdomyolysis and fasciitis induced by the COVID-19 mRNA vaccine: <https://pubmed.ncbi.nlm.nih.gov/34435250/>
124. COVID-19 vaccine-induced rhabdomyolysis: case report with literature review: <https://pubmed.ncbi.nlm.nih.gov/34186348/>.
125. GM1 ganglioside antibody and COVID-19-related Guillain Barre syndrome: case report, systemic review, and implications for vaccine development: <https://www.sciencedirect.com/science/article/pii/S2666354621000065>
126. Guillain-Barré syndrome after AstraZeneca COVID-19 vaccination: causal or casual association: <https://www.sciencedirect.com/science/article/pii/S0303846721004169>
127. Sensory Guillain-Barré syndrome after ChAdOx1 nCov-19 vaccine: report of two cases and review of the literature: <https://www.sciencedirect.com/science/article/pii/S0165572821002186>
128. Guillain-Barré syndrome after the first dose of SARS-CoV-2 vaccine: a temporary occurrence, not a causal association: <https://www.sciencedirect.com/science/article/pii/S2214250921000998>.
129. Guillain-Barré syndrome presenting as facial diplegia after vaccination with COVID-19: a case report: <https://www.sciencedirect.com/science/article/pii/S0736467921006442>
130. Guillain-Barré syndrome after the first injection of ChAdOx1 nCoV-19 vaccine: first report: <https://www.sciencedirect.com/science/article/pii/S0035378721005853>.
131. SARS-CoV-2 vaccines are not safe for those with Guillain-Barre syndrome following vaccination: <https://www.sciencedirect.com/science/article/pii/S2049080121005343>
132. Acute hyperactive encephalopathy following COVID-19 vaccination with dramatic response to methylprednisolone: a case report: <https://www.sciencedirect.com/science/article/pii/S2049080121007536>
133. Facial nerve palsy following administration of COVID-19 mRNA vaccines: analysis of self-report database: <https://www.sciencedirect.com/science/article/pii/S1201971221007049>
134. Neurological symptoms and neuroimaging alterations related to COVID-19 vaccine: cause or coincidence: <https://www.sciencedirect.com/science/article/pii/S0899707121003557>.
135. New-onset refractory status epilepticus after ChAdOx1 nCoV-19 vaccination: <https://www.sciencedirect.com/science/article/pii/S0165572821001569>
136. Acute myelitis and ChAdOx1 nCoV-19 vaccine: coincidental or causal association: <https://www.sciencedirect.com/science/article/pii/S0165572821002137>
137. Bell's palsy and SARS-CoV-2 vaccines: an unfolding story: <https://www.sciencedirect.com/science/article/pii/S1473309921002735>
138. Bell's palsy after the second dose of the Pfizer COVID-19 vaccine in a patient with a history of recurrent Bell's palsy: <https://www.sciencedirect.com/science/article/pii/S266635462100020X>
139. Acute-onset central serous retinopathy after immunization with COVID-19 mRNA vaccine.: <https://www.sciencedirect.com/science/article/pii/S2451993621001456>.
140. Bell's palsy after COVID-19 vaccination: case report: <https://www.sciencedirect.com/science/article/pii/S217358082100122X>.
141. An academic hospital experience assessing the risk of COVID-19 mRNA vaccine using patient's allergy history: <https://www.sciencedirect.com/science/article/pii/S2213219821007972>
142. COVID-19 vaccine-induced axillary and pectoral lymphadenopathy in PET: <https://www.sciencedirect.com/science/article/pii/S1930043321002612>
143. ANCA-associated vasculitis after Pfizer-BioNTech COVID-19 vaccine: <https://www.sciencedirect.com/science/article/pii/S0272638621007423>
144. Late cutaneous reactions after administration of COVID-19 mRNA vaccines: <https://www.sciencedirect.com/science/article/pii/S2213219821007996>
145. COVID-19 vaccine-induced rhabdomyolysis: case report with review of the literature: <https://www.sciencedirect.com/science/article/pii/S1871402121001880>
146. Clinical and pathologic correlates of skin reactions to COVID-19 vaccine, including V-REPP: a registry-based study: <https://www.sciencedirect.com/science/article/pii/S0190962221024427>
147. Thrombosis with thrombocytopenia syndrome associated with COVID-19 vaccines.: <https://www.sciencedirect.com/science/article/abs/pii/S0735675721004381>.
148. COVID-19 vaccine-associated anaphylaxis: a statement from the Anaphylaxis Committee of the World Allergy Organization.: <https://www.sciencedirect.com/science/article/pii/S1939455121000119>.
149. Cerebral venous sinus thrombosis negative for anti-PF4 antibody without thrombocytopenia after immunization with COVID-19 vaccine in an elderly, non-comorbid Indian male treated with conventional heparin-warfarin-based anticoagulation.: <https://www.sciencedirect.com/science/article/pii/S1871402121002046>.
150. Acute myocarditis after administration of BNT162b2 vaccine against COVID-19.: <https://www.sciencedirect.com/science/article/abs/pii/S188558572100133X>
151. Blood clots and bleeding after BNT162b2 and ChAdOx1 nCoV-19 vaccine: an analysis of European data.: <https://www.sciencedirect.com/science/article/pii/S0896841121000937>.
152. Immune thrombocytopenia associated with Pfizer-BioNTech's COVID-19 BNT162b2 mRNA vaccine.: <https://www.sciencedirect.com/science/article/pii/S2214250921002018>.
153. Bullous drug eruption after the second dose of COVID-19 mRNA-1273 (Moderna) vaccine: Case report: <https://www.sciencedirect.com/science/article/pii/S1876034121001878>.
154. COVID-19 RNA-based vaccines and the risk of prion disease: <https://scivisionpub.com/pdfs/covid19rna-based-vaccines-and-the-risk-of-prion-disease-1503.pdf>
155. This study notes that 115 pregnant women lost their babies, out of 827 who participated in a study on the safety of covid-19 vaccines: <https://www.nejm.org/doi/full/10.1056/NEJMoa2104983>.
156. Process-related impurities in the ChAdOx1 nCoV-19 vaccine: <https://www.researchsquare.com/article/rs-477964/v1>
157. COVID-19 mRNA vaccine causing CNS inflammation: a case series: <https://link.springer.com/article/10.1007/s00415-021-10780-7>
158. Allergic reactions, including anaphylaxis, after receiving the first dose of the Pfizer-BioNTech COVID-19 vaccine: <https://pubmed.ncbi.nlm.nih.gov/33475702/>
159. Allergic reactions to the first COVID-19 vaccine: a potential role of polyethylene glycol: <https://pubmed.ncbi.nlm.nih.gov/33320974/>
160. Pfizer Vaccine Raises Allergy Concerns: <https://pubmed.ncbi.nlm.nih.gov/33384356/>

161. Allergic reactions, including anaphylaxis, after receiving the first dose of Pfizer-BioNTech COVID-19 vaccine – United States, December 14-23, 2020: <https://pubmed.ncbi.nlm.nih.gov/33444297/>
162. Allergic reactions, including anaphylaxis, after receiving first dose of Modern COVID-19 vaccine – United States, December 21, 2020-January 10, 2021: <https://pubmed.ncbi.nlm.nih.gov/33507892/>
163. Reports of anaphylaxis after coronavirus disease vaccination 2019, South Korea, February 26-April 30, 2021: <https://pubmed.ncbi.nlm.nih.gov/34414880/>
164. Reports of anaphylaxis after receiving COVID-19 mRNA vaccines in the U.S.-Dec 14, 2020-Jan 18, 2021: <https://pubmed.ncbi.nlm.nih.gov/33576785/>
165. Immunization practices and risk of anaphylaxis: a current, comprehensive update of COVID-19 vaccination data: <https://pubmed.ncbi.nlm.nih.gov/34269740/>
166. Relationship between pre-existing allergies and anaphylactic reactions following administration of COVID-19 mRNA vaccine: <https://pubmed.ncbi.nlm.nih.gov/34215453/>
167. Anaphylaxis Associated with COVID-19 mRNA Vaccines: Approach to Allergy Research: <https://pubmed.ncbi.nlm.nih.gov/33932618/>
168. Severe Allergic Reactions after COVID-19 Vaccination with the Pfizer / BioNTech Vaccine in Great Britain and the USA: Position Statement of the German Allergy Societies: German Medical Association of Allergologists (AeDA), German Society for Allergology and Clinical Immunology (DGAKI) and Society for Pediatric Allergology and Environmental Medicine (GPA): <https://pubmed.ncbi.nlm.nih.gov/33643776/>
169. Allergic reactions and anaphylaxis to LNP-based COVID-19 vaccines: <https://pubmed.ncbi.nlm.nih.gov/33571463/>
170. Reported orofacial adverse effects from COVID-19 vaccines: the known and the unknown: <https://pubmed.ncbi.nlm.nih.gov/33527524/>
171. Cutaneous adverse effects of available COVID-19 vaccines: <https://pubmed.ncbi.nlm.nih.gov/34518015/>
172. Cumulative adverse event report of anaphylaxis following injections of COVID-19 mRNA vaccine (Pfizer-BioNTech) in Japan: the first month report: <https://pubmed.ncbi.nlm.nih.gov/34347278/>
173. COVID-19 vaccines increase the risk of anaphylaxis: <https://pubmed.ncbi.nlm.nih.gov/33685103/>
174. Biphasic anaphylaxis after exposure to the first dose of the Pfizer-BioNTech COVID-19 mRNA vaccine COVID-19: <https://pubmed.ncbi.nlm.nih.gov/34050949/>
175. Allergenic components of the mRNA-1273 vaccine for COVID-19: possible involvement of polyethylene glycol and IgG-mediated complement activation: <https://pubmed.ncbi.nlm.nih.gov/33657648/>
176. Polyethylene glycol (PEG) is a cause of anaphylaxis to Pfizer / BioNTech mRNA COVID-19 vaccine: <https://pubmed.ncbi.nlm.nih.gov/33825239/>
177. Acute allergic reactions to COVID-19 mRNA vaccines: <https://pubmed.ncbi.nlm.nih.gov/33683290/>
178. Polyethylene glycole allergy of the SARS CoV2 vaccine recipient: case report of a young adult recipient and management of future exposure to SARS-CoV2: <https://pubmed.ncbi.nlm.nih.gov/33919151/>
179. Elevated rates of anaphylaxis after vaccination with Pfizer BNT162b2 mRNA vaccine against COVID-19 in Japanese healthcare workers; a secondary analysis of initial post-approval safety data: <https://pubmed.ncbi.nlm.nih.gov/34128049/>
180. Allergic reactions and adverse events associated with administration of mRNA-based vaccines. A health system experience: <https://pubmed.ncbi.nlm.nih.gov/34474708/>
181. Allergic reactions to COVID-19 vaccines: statement of the Belgian Society of Allergy and Clinical Immunology (BelSACI): <https://www.tandfonline.com/doi/abs/10.1080/17843286.2021.1909447>
182. .IgE-mediated allergy to polyethylene glycol (PEG) as a cause of anaphylaxis to COVID-19 mRNA vaccines: <https://pubmed.ncbi.nlm.nih.gov/34318537/>
183. Allergic reactions after COVID-19 vaccination: putting the risk in perspective: <https://pubmed.ncbi.nlm.nih.gov/34463751/>
184. Anaphylactic reactions to COVID-19 mRNA vaccines: a call for further studies: <https://pubmed.ncbi.nlm.nih.gov/33846043/> 188.
185. Risk of severe allergic reactions to COVID-19 vaccines among patients with allergic skin disease: practical recommendations. An ETFAD position statement with external experts: <https://pubmed.ncbi.nlm.nih.gov/33752263/>
186. COVID-19 vaccine and death: causality algorithm according to the WHO eligibility diagnosis: <https://pubmed.ncbi.nlm.nih.gov/34073536/>
187. Fatal brain hemorrhage after COVID-19 vaccine: <https://pubmed.ncbi.nlm.nih.gov/33928772/>
188. A case series of skin reactions to COVID-19 vaccine in the Department of Dermatology at Loma Linda University: <https://pubmed.ncbi.nlm.nih.gov/34423106/>
189. Skin reactions reported after Moderna and Pfizer's COVID-19 vaccination: a study based on a registry of 414 cases: <https://pubmed.ncbi.nlm.nih.gov/33838206/>
190. Clinical and pathologic correlates of skin reactions to COVID-19 vaccine, including V-REPP: a registry-based study: <https://pubmed.ncbi.nlm.nih.gov/34517079/>
191. Skin reactions after vaccination against SARS-COV-2: a nationwide Spanish cross-sectional study of 405 cases: <https://pubmed.ncbi.nlm.nih.gov/34254291/>
192. Varicella zoster virus and herpes simplex virus reactivation after vaccination with COVID-19: review of 40 cases in an international dermatologic registry: <https://pubmed.ncbi.nlm.nih.gov/34487581/>
193. Immune thrombosis and thrombocytopenia (VITT) associated with the COVID-19 vaccine: diagnostic and therapeutic recommendations for a new syndrome: <https://pubmed.ncbi.nlm.nih.gov/33987882/>
194. Laboratory testing for suspicion of COVID-19 vaccine-induced thrombotic (immune) thrombocytopenia: <https://pubmed.ncbi.nlm.nih.gov/34138513/>
195. Intracerebral hemorrhage due to thrombosis with thrombocytopenia syndrome after COVID-19 vaccination: the first fatal case in Korea: <https://pubmed.ncbi.nlm.nih.gov/34402235/>
196. Risk of thrombocytopenia and thromboembolism after covid-19 vaccination and positive SARS-CoV-2 tests: self-controlled case series study: <https://pubmed.ncbi.nlm.nih.gov/34446426/>
197. Vaccine-induced immune thrombotic thrombocytopenia and cerebral venous sinus thrombosis after covid-19 vaccination; a systematic review: <https://pubmed.ncbi.nlm.nih.gov/34365148/>.
198. Nerve and muscle adverse events after vaccination with COVID-19: a systematic review and meta-analysis of clinical trials: <https://pubmed.ncbi.nlm.nih.gov/34452064/>.
199. A rare case of cerebral venous thrombosis and disseminated intravascular coagulation temporally associated with administration of COVID-19 vaccine: <https://pubmed.ncbi.nlm.nih.gov/33917902/>
200. Primary adrenal insufficiency associated with thrombotic immune thrombocytopenia induced by Oxford-AstraZeneca ChAdOx1 nCoV-19

- vaccine (VITT): <https://pubmed.ncbi.nlm.nih.gov/34256983/>
201. Acute cerebral venous thrombosis and pulmonary artery embolism associated with the COVID-19 vaccine: <https://pubmed.ncbi.nlm.nih.gov/34247246/>.
 202. Thromboaspiration infusion and fibrinolysis for portomesenteric thrombosis after administration of AstraZeneca COVID-19 vaccine: <https://pubmed.ncbi.nlm.nih.gov/34132839/>
 203. 59-year-old woman with extensive deep venous thrombosis and pulmonary thromboembolism 7 days after a first dose of Pfizer-BioNTech BNT162b2 mRNA vaccine COVID-19: <https://pubmed.ncbi.nlm.nih.gov/34117206/>
 204. Cerebral venous thrombosis and vaccine-induced thrombocytopenia. a. Oxford-AstraZeneca COVID-19: a missed opportunity for a rapid return on experience: <https://pubmed.ncbi.nlm.nih.gov/34033927/>
 205. Myocarditis and other cardiovascular complications of mRNA-based COVID-19 vaccines: <https://pubmed.ncbi.nlm.nih.gov/34277198/>
 206. Pericarditis after administration of COVID-19 mRNA BNT162b2 vaccine: <https://pubmed.ncbi.nlm.nih.gov/34364831/>
 207. Unusual presentation of acute pericarditis after vaccination against SARS-CoV-2 mRNA-1273 Moderna: <https://pubmed.ncbi.nlm.nih.gov/34447639/>
 208. Case report: acute myocarditis after second dose of SARS-CoV-2 mRNA-1273 vaccine mRNA-1273: <https://pubmed.ncbi.nlm.nih.gov/34514306/>
 209. Immune-mediated disease outbreaks or recent-onset disease in 27 subjects after mRNA/DNA vaccination against SARS-CoV-2: <https://pubmed.ncbi.nlm.nih.gov/33946748/>
 210. Insights from a murine model of myopericarditis induced by COVID-19 mRNA vaccine: could accidental intravenous injection of a vaccine induce myopericarditis: <https://pubmed.ncbi.nlm.nih.gov/34453510/>
 211. Immune thrombocytopenia in a 22-year-old post Covid-19 vaccine: <https://pubmed.ncbi.nlm.nih.gov/33476455/>
 212. propylthiouracil-induced neutrophil anti-cytoplasmic antibody-associated vasculitis after COVID-19 vaccination: <https://pubmed.ncbi.nlm.nih.gov/34451967/>
 213. Secondary immune thrombocytopenia (ITP) associated with ChAdOx1 Covid-19 vaccine: case report: <https://pubmed.ncbi.nlm.nih.gov/34377889/>
 214. Thrombosis with thrombocytopenia syndrome (TTS) following AstraZeneca ChAdOx1 nCoV-19 (AZD1222) COVID-19 vaccination: risk-benefit analysis for persons <60 years in Australia: <https://pubmed.ncbi.nlm.nih.gov/34272095/>
 215. COVID-19 vaccination association and facial nerve palsy: A case-control study: <https://pubmed.ncbi.nlm.nih.gov/34165512/>
 216. The association between COVID-19 vaccination and Bell's palsy: <https://pubmed.ncbi.nlm.nih.gov/34411533/>
 217. Bell's palsy after COVID-19 vaccination: <https://pubmed.ncbi.nlm.nih.gov/33611630/>
 218. Acute transverse myelitis (ATM): clinical review of 43 patients with COVID-19-associated ATM and 3 serious adverse events of post-vaccination ATM with ChAdOx1 nCoV-19 vaccine (AZD1222): <https://pubmed.ncbi.nlm.nih.gov/33981305/>
 219. Bell's palsy after 24 hours of mRNA-1273 SARS-CoV-2 mRNA-1273 vaccine: <https://pubmed.ncbi.nlm.nih.gov/34336436/>
 220. Sequential contralateral facial nerve palsy after first and second doses of COVID-19 vaccine: <https://pubmed.ncbi.nlm.nih.gov/34281950/>
 221. Transverse myelitis geïnduceerd door SARS-CoV-2-vaccinatie: <https://pubmed.ncbi.nlm.nih.gov/34458035/>
 222. Perifere aangezichtszenuwverlamming na vaccinatie met BNT162b2 (COVID-19): <https://pubmed.ncbi.nlm.nih.gov/33734623/>
 223. Acute abducens zenuwverlamming na COVID-19-vaccinatie: <https://pubmed.ncbi.nlm.nih.gov/34044114/> .
 224. Aangezichtszenuwverlamming na toediening van COVID-19-mRNA-vaccins: analyse van zelfrapportagedatabase: <https://pubmed.ncbi.nlm.nih.gov/34492394/>
 225. Voorbijgaande oculomotorische verlamming na toediening van RNA-1273-messengervaccin voor SARS-CoV-2-diplopie na COVID-19-vaccin: <https://pubmed.ncbi.nlm.nih.gov/34369471/>
 226. Ziekte van Bell na Ad26.COV2.S COVID-19-vaccinatie: <https://pubmed.ncbi.nlm.nih.gov/34014316/>
 227. Bell's palsy na COVID-19-vaccinatie: casusrapport: <https://pubmed.ncbi.nlm.nih.gov/34330676/>
 228. Een geval van acute demyeliniserende polyradiculoneuropathie met bilaterale gezichtsverlamming na vaccinatie met ChAdOx1 nCoV-19: <https://pubmed.ncbi.nlm.nih.gov/34272622/>
 229. Syndroom van Guillain Barré na vaccinatie met mRNA-1273 tegen COVID-19: <https://pubmed.ncbi.nlm.nih.gov/34477091/>
 230. Acute aangezichtsverlamming als mogelijke complicatie van SARS-CoV-2-vaccinatie: <https://pubmed.ncbi.nlm.nih.gov/33975372/> .
 231. Ziekte van Bell na COVID-19-vaccinatie met hoge antilichaamrespons in CSF: <https://pubmed.ncbi.nlm.nih.gov/34322761/> .
 232. Parsonage-Turner-syndroom geassocieerd met SARS-CoV-2- of SARS-CoV-2-vaccinatie. Commentaar op: "Neuralgische amyotrofie en COVID-19-infectie: 2 gevallen van bijkomende spinale zenuwverlamming" door Coll et al. *Gewrichtswervelkolom* 2021; 88: 10519: <https://pubmed.ncbi.nlm.nih.gov/34139321/> .
 233. Bell's palsy na een enkele dosis vaccin-mRNA. SARS-CoV-2: casusrapport: <https://pubmed.ncbi.nlm.nih.gov/34032902/> .
 234. Auto-immuunhepatitis ontwikkelt zich na vaccin tegen coronavirusziekte 2019 (COVID-19): oorzakelijk verband of slachtoffer?: <https://pubmed.ncbi.nlm.nih.gov/33862041/>
 235. Auto-immune hepatitis veroorzaakt door vaccinatie tegen SARS-CoV-2: <https://pubmed.ncbi.nlm.nih.gov/34332438/>
 236. Acute auto-immuunachtige hepatitis met atypisch antimitochondriaal antilichaam na vaccinatie met COVID-19-mRNA: een nieuwe klinische entiteit: <https://pubmed.ncbi.nlm.nih.gov/34293683/> .
 237. Auto-immune hepatitis na COVID-vaccin: <https://pubmed.ncbi.nlm.nih.gov/34225251/>
 238. Een nieuw geval van bifaciale diplegievariant van het syndroom van Guillain-Barré na vaccinatie met Janssen COVID-19: <https://pubmed.ncbi.nlm.nih.gov/34449715/>
 239. Vergelijking van vaccin-geïnduceerde trombotische gebeurtenissen tussen ChAdOx1 nCoV-19- en Ad26.COV2.S-vaccins: <https://pubmed.ncbi.nlm.nih.gov/34139631/> .
 240. Bilaterale superieure oftalmische veneuze trombose, ischemische beroerte en immuuntrombocytopenie na vaccinatie met ChAdOx1 nCoV-19: <https://pubmed.ncbi.nlm.nih.gov/33864750/>
 241. Diagnose en behandeling van cerebrale veneuze sinustrombose met vaccin-geïnduceerde immuun-immune trombotische trombocytopenie: <https://pubmed.ncbi.nlm.nih.gov/33914590/>
 242. Veneuze sinustrombose na vaccinatie met ChAdOx1 nCoV-19: <https://pubmed.ncbi.nlm.nih.gov/34420802/>
 243. Cerebrale veneuze sinustrombose na vaccinatie tegen SARS-CoV-2: een analyse van gevallen gemeld aan het Europees Geneesmiddelenbureau: <https://pubmed.ncbi.nlm.nih.gov/34293217/>
 244. Risico op trombocytopenie en trombo-embolie na covid-19-vaccinatie en positieve SARS-CoV-2-tests: zelfgecontroleerde case-serie-studie: <https://pubmed.ncbi.nlm.nih.gov/34446426/>

245. Bloedstolsels en bloedingen na vaccinatie tegen BNT162b2 en ChAdOx1 nCoV-19: een analyse van Europese gegevens: <https://pubmed.ncbi.nlm.nih.gov/34174723/>
246. Arteriële voorvallen, veneuze trombo-embolie, trombocytopenie en bloeding na vaccinatie met Oxford-AstraZeneca ChAdOx1-S in Denemarken en Noorwegen: cohortonderzoek op populatiebasis: <https://pubmed.ncbi.nlm.nih.gov/33952445/>
247. Eerste dosis ChAdOx1 en BNT162b2 COVID-19-vaccins en trombocytopenische, trombo-embolische en hemorragische voorvallen in Schotland: <https://pubmed.ncbi.nlm.nih.gov/34108714/>
248. Cerebrale veneuze trombose geassocieerd met COVID-19-vaccin in Duitsland: <https://pubmed.ncbi.nlm.nih.gov/34288044/>
249. Kwaadaardig herseninfarct na vaccinatie met ChAdOx1 nCoV-19: een catastrofale variant van vaccin-geïnduceerde immuungemedieerde trombotische trombocytopenie: <https://pubmed.ncbi.nlm.nih.gov/34341358/>
250. coeliakie en miltslagadertrombose gecompliceerd door miltinfarct 7 dagen na de eerste dosis Oxford-vaccin, oorzakelijk verband of toeval: <https://pubmed.ncbi.nlm.nih.gov/34261633/> .
251. Primaire bijnierinsufficiëntie geassocieerd met Oxford-AstraZeneca ChAdOx1 nCoV-19 (VITT) vaccin-geïnduceerde immuuntrombotische trombocytopenie: <https://pubmed.ncbi.nlm.nih.gov/34256983/>
252. Trombocytopenie na COVID-19-vaccinatie: <https://pubmed.ncbi.nlm.nih.gov/34332437/> .
253. Cerebrale veneuze sinustrombose geassocieerd met trombocytopenie na COVID-19-vaccinatie: <https://pubmed.ncbi.nlm.nih.gov/33845870/>
254. Trombose met trombocytopeniesyndroom na COVID-19-immunisatie: <https://pubmed.ncbi.nlm.nih.gov/34236343/>
255. Acuut hartinfarct binnen 24 uur na COVID-19 vaccinatie: <https://pubmed.ncbi.nlm.nih.gov/34364657/> .
256. Bilaterale acute maculaire neuroretinopathie na SARS-CoV-2-vaccinatie: <https://pubmed.ncbi.nlm.nih.gov/34287612/>
257. centrale veneuze sinustrombose met subarachnoïdale bloeding na COVID-19 mRNA-vaccinatie: zijn deze meldingen louter toevallig: <https://pubmed.ncbi.nlm.nih.gov/34478433/>
258. Intracerebral hemorrhage due to thrombosis with thrombocytopenia syndrome after COVID-19 vaccination: the first fatal case in Korea: <https://pubmed.ncbi.nlm.nih.gov/34402235/>
259. Cerebral venous sinus thrombosis negative for anti-PF4 antibody without thrombocytopenia after immunization with COVID-19 vaccine in a non-comorbid elderly Indian male treated with conventional heparin-warfarin-based anticoagulation: <https://pubmed.ncbi.nlm.nih.gov/34186376/>
260. Cerebral venous sinus thrombosis 2 weeks after first dose of SARS-CoV-2 mRNA vaccine: <https://pubmed.ncbi.nlm.nih.gov/34101024/>
261. A case of multiple thrombocytopenia and thrombosis following vaccination with ChAdOx1 nCoV-19 against SARS-CoV-2: <https://pubmed.ncbi.nlm.nih.gov/34137813/>
262. Vaccine-induced thrombotic thrombocytopenia: the elusive link between thrombosis and adenovirus-based SARS-CoV-2 vaccines: <https://pubmed.ncbi.nlm.nih.gov/34191218/>
263. Acute ischemic stroke revealing immune thrombotic thrombocytopenia induced by ChAdOx1 nCoV-19 vaccine: impact on recanalization strategy: <https://pubmed.ncbi.nlm.nih.gov/34175640/>
264. New-onset refractory status epilepticus after ChAdOx1 nCoV-19 vaccine: <https://pubmed.ncbi.nlm.nih.gov/34153802/>
265. Thrombosis with thrombocytopenia syndrome associated with COVID-19 viral vector vaccines: <https://pubmed.ncbi.nlm.nih.gov/34092488/>
266. Pulmonary embolism, transient ischemic attack, and thrombocytopenia after Johnson & Johnson COVID-19 vaccine: <https://pubmed.ncbi.nlm.nih.gov/34261635/>
267. Thromboaspiration infusion and fibrinolysis for portomesenteric thrombosis after administration of the AstraZeneca COVID-19 vaccine: <https://pubmed.ncbi.nlm.nih.gov/34132839/>.
268. Spontaneous HIT syndrome: knee replacement, infection, and parallels with vaccine-induced immune thrombotic thrombocytopenia: <https://pubmed.ncbi.nlm.nih.gov/34144250/>
269. Deep venous thrombosis (DVT) occurring shortly after second dose of SARS-CoV-2 mRNA vaccine: <https://pubmed.ncbi.nlm.nih.gov/33687691/>
270. Procoagulant antibody-mediated procoagulant platelets in immune thrombotic thrombocytopenia associated with SARS-CoV-2 vaccination: <https://pubmed.ncbi.nlm.nih.gov/34011137/>.
271. Vaccine-induced immune thrombotic thrombocytopenia causing a severe form of cerebral venous thrombosis with high mortality rate: a case series: <https://pubmed.ncbi.nlm.nih.gov/34393988/>.
272. Procoagulant microparticles: a possible link between vaccine-induced immune thrombocytopenia (VITT) and cerebral sinus venous thrombosis: <https://pubmed.ncbi.nlm.nih.gov/34129181/>.
273. Atypical thrombosis associated with the vaccine VaxZevria® (AstraZeneca): data from the French network of regional pharmacovigilance centers: <https://pubmed.ncbi.nlm.nih.gov/34083026/>.
274. Acute cerebral venous thrombosis and pulmonary artery embolism associated with the COVID-19 vaccine: <https://pubmed.ncbi.nlm.nih.gov/34247246/>.
275. Vaccine-induced thrombosis and thrombocytopenia with bilateral adrenal haemorrhage: <https://pubmed.ncbi.nlm.nih.gov/34235757/>.
276. Palmar digital vein thrombosis after Oxford-AstraZeneca COVID-19 vaccination: <https://pubmed.ncbi.nlm.nih.gov/34473841/>.
277. Cutaneous thrombosis associated with cutaneous necrosis following Oxford-AstraZeneca COVID-19 vaccination: <https://pubmed.ncbi.nlm.nih.gov/34189756/>
278. Cerebral venous thrombosis following COVID-19 vaccination: <https://pubmed.ncbi.nlm.nih.gov/34045111/>.
279. Lipschütz ulcers after AstraZeneca COVID-19 vaccination: <https://pubmed.ncbi.nlm.nih.gov/34366434/>.
280. Amyotrophic Neuralgia secondary to Vaxzevri vaccine (AstraZeneca) COVID-19: <https://pubmed.ncbi.nlm.nih.gov/34330677/>
281. Thrombosis with thrombocytopenia after Messenger vaccine RNA-1273: <https://pubmed.ncbi.nlm.nih.gov/34181446/>
282. Intracerebral hemorrhage twelve days after vaccination with ChAdOx1 nCoV-19: <https://pubmed.ncbi.nlm.nih.gov/34477089/>
283. Thrombotic thrombocytopenia after vaccination with COVID-19: in search of the underlying mechanism: <https://pubmed.ncbi.nlm.nih.gov/34071883/>
284. Coronavirus (COVID-19) Vaccine-induced immune thrombotic thrombocytopenia (VITT): <https://pubmed.ncbi.nlm.nih.gov/34033367/>
285. Comparison of adverse drug reactions among four COVID-19 vaccines in Europe using the EudraVigilance database: Thrombosis in unusual sites: <https://pubmed.ncbi.nlm.nih.gov/34375510/>
286. Immunoglobulin adjuvant for vaccine-induced immune thrombotic thrombocytopenia: <https://pubmed.ncbi.nlm.nih.gov/34107198/>
287. Severe vaccine-induced thrombotic thrombocytopenia following vaccination with COVID-19: an autopsy case report and review of the literature: <https://pubmed.ncbi.nlm.nih.gov/34355379/>.

288. A case of acute pulmonary embolism after immunization with SARS-CoV-2 mRNA: <https://pubmed.ncbi.nlm.nih.gov/34452028/>
289. Neurosurgical considerations regarding decompressive craniectomy for intracerebral hemorrhage after SARS-CoV-2 vaccination in vaccine-induced thrombotic thrombocytopenia-VITT: <https://pubmed.ncbi.nlm.nih.gov/34202817/>
290. Thrombosis and SARS-CoV-2 vaccines: vaccine-induced immune thrombotic thrombocytopenia: <https://pubmed.ncbi.nlm.nih.gov/34237213/>
291. Acquired thrombotic thrombocytopenic thrombocytopenic purpura: a rare disease associated with the BNT162b2 vaccine: <https://pubmed.ncbi.nlm.nih.gov/34105247/>
292. Immune complexes, innate immunity and NETosis in ChAdOx1 vaccine-induced thrombocytopenia: <https://pubmed.ncbi.nlm.nih.gov/34405870/>
293. Sensory Guillain-Barré syndrome following ChAdOx1 nCov-19 vaccine: report of two cases and review of the literature: <https://pubmed.ncbi.nlm.nih.gov/34416410/>
294. Vogt-Koyanagi-Harada syndrome after COVID-19 and ChAdOx1 nCoV-19 (AZD1222) vaccination: <https://pubmed.ncbi.nlm.nih.gov/34462013/>
295. Reactivation of Vogt-Koyanagi-Harada disease under control for more than 6 years, after anti-SARS-CoV-2 vaccination: <https://pubmed.ncbi.nlm.nih.gov/34224024/>
296. Post-vaccinal encephalitis after ChAdOx1 nCov-19: <https://pubmed.ncbi.nlm.nih.gov/34324214/>
297. Neurological symptoms and neuroimaging alterations related to COVID-19 vaccine: cause or coincidence?: <https://pubmed.ncbi.nlm.nih.gov/34507266/>
298. Fatal systemic capillary leak syndrome after SARS-COV-2 vaccination in a patient with multiple myeloma: <https://pubmed.ncbi.nlm.nih.gov/34459725/>
299. Polyarthralgia and myalgia syndrome after vaccination with ChAdOx1 nCOV-19: <https://pubmed.ncbi.nlm.nih.gov/34463066/>
300. Three cases of subacute thyroiditis after SARS-CoV-2 vaccination: post-vaccination ASIA syndrome: <https://pubmed.ncbi.nlm.nih.gov/34043800/>
301. Facial diplegia: a rare and atypical variant of Guillain-Barré syndrome and the Ad26.CO2.S vaccine: <https://pubmed.ncbi.nlm.nih.gov/34447646/>
302. Association between ChAdOx1 nCoV-19 vaccination and bleeding episodes: large population-based cohort study: <https://pubmed.ncbi.nlm.nih.gov/34479760/>
303. fulminant myocarditis and systemic hyperinflammation temporally associated with BNT162b2 COVID-19 mRNA vaccination in two patients: <https://pubmed.ncbi.nlm.nih.gov/34416319/>
304. Adverse effects reported after COVID-19 vaccination in a tertiary care hospital, centered on cerebral venous sinus thrombosis (CVST): <https://pubmed.ncbi.nlm.nih.gov/34092166/>
305. Induction and exacerbation of subacute cutaneous lupus erythematosus erythematosus after mRNA- or adenoviral vector-based SARS-CoV-2 vaccination: <https://pubmed.ncbi.nlm.nih.gov/34291477/>
306. Petechiae and peeling of fingers after immunization with BTN162b2 messenger RNA (mRNA)-based COVID-19 vaccine: <https://pubmed.ncbi.nlm.nih.gov/34513435/>
307. Hepatitis C virus reactivation after COVID-19 vaccination: a case report: <https://pubmed.ncbi.nlm.nih.gov/34512037/>
308. Bilateral immune-mediated keratolysis after immunization with SARS-CoV-2 recombinant viral vector vaccine: <https://pubmed.ncbi.nlm.nih.gov/34483273/>
309. Immune-mediated thrombocytopenic purpura after Pfizer-BioNTech COVID-19 vaccine in an elderly woman: <https://pubmed.ncbi.nlm.nih.gov/34513446/>
310. Platelet activation and modulation in thrombosis with thrombocytopenia syndrome associated with the ChAdO × 1 nCov-19 vaccine: <https://pubmed.ncbi.nlm.nih.gov/34474550/>
311. Reactive arthritis after COVID-19 vaccination: <https://pubmed.ncbi.nlm.nih.gov/34033732/>
312. Two cases of Graves' disease after SARS-CoV-2 vaccination: an autoimmune / inflammatory syndrome induced by adjuvants: <https://pubmed.ncbi.nlm.nih.gov/33858208/>
313. Acute relapse and impaired immunization after COVID-19 vaccination in a patient with multiple sclerosis treated with rituximab: <https://pubmed.ncbi.nlm.nih.gov/34015240/>
314. Widespread fixed bullous drug eruption after vaccination with ChAdOx1 nCoV-19: <https://pubmed.ncbi.nlm.nih.gov/34482558/>
315. COVID-19 mRNA vaccine causing CNS inflammation: a case series: <https://pubmed.ncbi.nlm.nih.gov/34480607/>
316. Thymic hyperplasia after Covid-19 mRNA-based vaccination with Covid-19: <https://pubmed.ncbi.nlm.nih.gov/34462647/>
317. Acute disseminated encephalomyelitis following vaccination against SARS-CoV-2: <https://pubmed.ncbi.nlm.nih.gov/34325334/>
318. Tolosa-Hunt syndrome occurring after COVID-19 vaccination: <https://pubmed.ncbi.nlm.nih.gov/34513398/>
319. Systemic capillary extravasation syndrome following vaccination with ChAdOx1 nCOV-19 (Oxford-AstraZeneca): <https://pubmed.ncbi.nlm.nih.gov/34362727/>
320. Immune-mediated thrombocytopenia associated with Ad26.CO2.S vaccine (Janssen; Johnson & Johnson): <https://pubmed.ncbi.nlm.nih.gov/34469919/>
321. Transient thrombocytopenia with glycoprotein-specific platelet autoantibodies after vaccination with Ad26.CO2.S: case report: <https://pubmed.ncbi.nlm.nih.gov/34516272/>
322. Acute hyperactive encephalopathy following COVID-19 vaccination with dramatic response to methylprednisolone: case report: <https://pubmed.ncbi.nlm.nih.gov/34512961/>
323. Transient cardiac injury in adolescents receiving the BNT162b2 mRNA COVID-19 vaccine: <https://pubmed.ncbi.nlm.nih.gov/34077949/>
324. Autoimmune hepatitis developing after ChAdOx1 nCoV-19 vaccine (Oxford-AstraZeneca): <https://pubmed.ncbi.nlm.nih.gov/34171435/>
325. Severe relapse of multiple sclerosis after COVID-19 vaccination: a case report: <https://pubmed.ncbi.nlm.nih.gov/34447349/>
326. Lymphohistocytic myocarditis after vaccination with the COVID-19 viral vector Ad26.CO2.S: <https://pubmed.ncbi.nlm.nih.gov/34514078/>
327. Hemophagocytic lymphohistiocytosis after vaccination with ChAdOx1 nCov-19: <https://pubmed.ncbi.nlm.nih.gov/34406660/>
328. IgA vasculitis in adult patient after vaccination with ChadOx1 nCoV-19: <https://pubmed.ncbi.nlm.nih.gov/34509658/>
329. A case of leukocytoclastic vasculitis after vaccination with a SARS-CoV2 vaccine: case report: <https://pubmed.ncbi.nlm.nih.gov/34196469/>
330. Onset / outbreak of psoriasis after Corona virus ChAdOx1 nCoV-19 vaccine (Oxford-AstraZeneca / Covishield): report of two cases: <https://pubmed.ncbi.nlm.nih.gov/34350668/>
331. Hailey-Hailey disease exacerbation after SARS-CoV-2 vaccination: <https://pubmed.ncbi.nlm.nih.gov/34436620/>
332. Supraclavicular lymphadenopathy after COVID-19 vaccination in Korea: serial follow-up by ultrasonography: <https://pubmed.ncbi.nlm.nih.gov/34436620/>

/34116295/.

333. COVID-19 vaccine, immune thrombotic thrombocytopenia, jaundice, hyperviscosity: concern in cases with underlying hepatic problems: <https://pubmed.ncbi.nlm.nih.gov/34509271/>.
334. Report of the International Cerebral Venous Thrombosis Consortium on cerebral venous thrombosis after SARS-CoV-2 vaccination: <https://pubmed.ncbi.nlm.nih.gov/34462996/>
335. Immune thrombocytopenia after vaccination during the COVID-19 pandemic: <https://pubmed.ncbi.nlm.nih.gov/34435486/>
336. COVID-19: lessons from the Norwegian tragedy should be taken into account in planning for vaccine launch in less developed/developing countries: <https://pubmed.ncbi.nlm.nih.gov/34435142/>
337. Rituximab-induced acute lympholysis and pancytopenia following vaccination with COVID-19: <https://pubmed.ncbi.nlm.nih.gov/34429981/>
338. Exacerbation of plaque psoriasis after COVID-19 inactivated mRNA and BNT162b2 vaccines: report of two cases: <https://pubmed.ncbi.nlm.nih.gov/34427024/>
339. Vaccine-induced interstitial lung disease: a rare reaction to COVID-19 vaccine: <https://pubmed.ncbi.nlm.nih.gov/34510014/>.
340. Vesiculobullous cutaneous reactions induced by COVID-19 mRNA vaccine: report of four cases and review of the literature: <https://pubmed.ncbi.nlm.nih.gov/34236711/>
341. Vaccine-induced thrombocytopenia with severe headache: <https://pubmed.ncbi.nlm.nih.gov/34525282/>
342. Acute perimyocarditis after the first dose of COVID-19 mRNA vaccine: <https://pubmed.ncbi.nlm.nih.gov/34515024/>
343. Rhabdomyolysis and fasciitis induced by COVID-19 mRNA vaccine: <https://pubmed.ncbi.nlm.nih.gov/34435250/>.
344. Rare cutaneous adverse effects of COVID-19 vaccines: a case series and review of the literature: <https://pubmed.ncbi.nlm.nih.gov/34363637/>
345. Immune thrombocytopenia associated with the Pfizer-BioNTech COVID-19 mRNA vaccine BNT162b2: <https://www.sciencedirect.com/science/article/pii/S2214250921002018>
346. Secondary immune thrombocytopenia putatively attributable to COVID-19 vaccination: <https://casereports.bmj.com/content/14/5/e242220.abstract>.
347. Immune thrombocytopenia following Pfizer-BioNTech BNT162b2 mRNA COVID-19 vaccine: <https://pubmed.ncbi.nlm.nih.gov/34155844/>
348. Newly diagnosed idiopathic thrombocytopenia after COVID-19 vaccine administration: <https://www.ncbi.nlm.nih.gov/pmc/articles/PMC8176657/>.
349. Idiopathic thrombocytopenic purpura and the Modern Covid-19 vaccine: [https://www.annemergmed.com/article/S0196-0644\(21\)00122-0/fulltext](https://www.annemergmed.com/article/S0196-0644(21)00122-0/fulltext).
350. Thrombocytopenia after Pfizer and Moderna SARS vaccination – CoV -2: <https://www.ncbi.nlm.nih.gov/pmc/articles/PMC8014568/>.
351. Immune thrombocytopenic purpura and acute liver injury after COVID-19 vaccination: <https://casereports.bmj.com/content/14/7/e242678>.
352. Collection of complement-mediated and autoimmune-mediated hematologic conditions after SARS-CoV-2 vaccination: <https://ashpublications.org/bloodadvances/article/5/13/2794/476324/Autoimmune-and-complement-mediated-hematologic>
353. Petechial rash associated with CoronaVac vaccination: first report of cutaneous side effects before phase 3 results: <https://ejhp.bmj.com/content/early/2021/05/23/ejhp2021-002794>
354. COVID-19 vaccines induce severe hemolysis in paroxysmal nocturnal hemoglobinuria: <https://ashpublications.org/blood/article/137/26/3670/475905/COVID-19-vaccines-induce-severe-hemolysis-in>
355. Cerebral venous thrombosis associated with COVID-19 vaccine in Germany: <https://pubmed.ncbi.nlm.nih.gov/34288044/>.
356. Cerebral venous sinus thrombosis after COVID-19 vaccination : Neurological and radiological management: <https://pubmed.ncbi.nlm.nih.gov/34327553/>.
357. Cerebral venous thrombosis and thrombocytopenia after COVID-19 vaccination: <https://pubmed.ncbi.nlm.nih.gov/33878469/>.
358. Cerebral venous sinus thrombosis and thrombocytopenia after COVID-19 vaccination: report of two cases in the United Kingdom: <https://pubmed.ncbi.nlm.nih.gov/33857630/>.
359. Cerebral venous thrombosis induced by SARS-CoV-2 vaccine: <https://pubmed.ncbi.nlm.nih.gov/34090750/>.
360. Carotid artery immune thrombosis induced by adenovirus-vectored COVID-19 vaccine: case report: <https://pubmed.ncbi.nlm.nih.gov/34312301/>.
361. Cerebral venous sinus thrombosis associated with vaccine-induced thrombotic thrombocytopenia: <https://pubmed.ncbi.nlm.nih.gov/34333995/>
362. The roles of platelets in COVID-19-associated coagulopathy and vaccine-induced immune-immune thrombotic thrombocytopenia: <https://pubmed.ncbi.nlm.nih.gov/34455073/>
363. Cerebral venous thrombosis after the BNT162b2 mRNA SARS-CoV-2 vaccine: <https://pubmed.ncbi.nlm.nih.gov/34111775/>.
364. Cerebral venous thrombosis after COVID-19 vaccination: <https://pubmed.ncbi.nlm.nih.gov/34045111/>
365. Lethal cerebral venous sinus thrombosis after COVID-19 vaccination: <https://pubmed.ncbi.nlm.nih.gov/33983464/>
366. Cerebral venous sinus thrombosis in the U.S. population, After SARS-CoV-2 vaccination with adenovirus and after COVID-19: <https://pubmed.ncbi.nlm.nih.gov/34116145/>
367. Cerebral venous thrombosis after COVID-19 vaccination: is the risk of thrombosis increased by intravascular administration of the vaccine: <https://pubmed.ncbi.nlm.nih.gov/34286453/>.
368. Centrale veneuze sinustrombose met subarachnoïdale bloeding na COVID-19 mRNA-vaccinatie: zijn deze meldingen louter toevallig: <https://pubmed.ncbi.nlm.nih.gov/34478433/>
369. Cerebrale veneuze sinustrombose na ChAdOx1 nCov-19-vaccinatie met een misleidende eerste hersen-MRI: <https://pubmed.ncbi.nlm.nih.gov/34244448/>
370. Vroege resultaten van behandeling met bivalirudine voor trombotische trombocytopenie en cerebrale veneuze sinustrombose na vaccinatie met Ad26.COV2.S: <https://pubmed.ncbi.nlm.nih.gov/34226070/>
371. Cerebrale veneuze sinustrombose geassocieerd met trombocytopenie na vaccinatie door COVID-19: <https://pubmed.ncbi.nlm.nih.gov/33845870/> .
372. Cerebrale veneuze sinustrombose 2 weken na de eerste dosis SARS-CoV-2 mRNA-vaccin: <https://pubmed.ncbi.nlm.nih.gov/34101024/> .
373. Vaccin-geïnduceerde immuuntrombotische trombocytopenie die een ernstige vorm van cerebrale veneuze trombose veroorzaakt met een hoog sterftecijfer: een casusreeks: <https://pubmed.ncbi.nlm.nih.gov/34393988/> .
374. Adenovirus-interacties met bloedplaatjes en coagulatie en vaccin-geassocieerd auto-immune trombocytopenie trombosesyndroom: <https://pubmed.ncbi.nlm.nih.gov/34407607/> .
375. Hoofdpijn toegeschreven aan COVID-19 (SARS-CoV-2 coronavirus) vaccinatie met het ChAdOx1 nCov-19 (AZD1222) vaccin: een

- multicenter observationele cohortstudie: <https://pubmed.ncbi.nlm.nih.gov/34313952/>
376. Bijwerkingen gemeld na COVID-19-vaccinatie in een tertiair ziekenhuis, focus op cerebrale veneuze sinustrombose (CVST): <https://pubmed.ncbi.nlm.nih.gov/34092166/>
 377. Cerebrale veneuze sinustrombose na vaccinatie tegen SARS-CoV-2: een analyse van gevallen gemeld aan het Europees Geneesmiddelenbureau: <https://pubmed.ncbi.nlm.nih.gov/34293217/>
 378. Een zeldzaam geval van een Aziatische man van middelbare leeftijd met cerebrale veneuze trombose na COVID-19 AstraZeneca-vaccinatie: <https://pubmed.ncbi.nlm.nih.gov/34274191/>
 379. Cerebrale veneuze sinustrombose negatief voor anti-PF4-antilichaam zonder trombocytopenie na immunisatie met COVID-19-vaccin bij een niet-comorbide oudere Indiase man die werd behandeld met conventionele op heparine-warfarine gebaseerde antistolling: <https://pubmed.ncbi.nlm.nih.gov/34186376/>
 380. Arteriële voorvallen, veneuze trombo-embolie, trombocytopenie en bloeding na vaccinatie met Oxford-AstraZeneca ChAdOx1-S in Denemarken en Noorwegen: cohortonderzoek op populatiebasis: <https://pubmed.ncbi.nlm.nih.gov/33952445/>
 381. Procoagulerende microdeeltjes: een mogelijk verband tussen vaccin-geïnduceerde immuuntrombocytopenie (VITT) en cerebrale sinus veneuze trombose: <https://pubmed.ncbi.nlm.nih.gov/34129181/>
 382. S. casusrapporten van cerebrale veneuze sinustrombose met trombocytopenie na vaccinatie met Ad26.COVS.2, 2 maart - 21 april 2021: <https://pubmed.ncbi.nlm.nih.gov/33929487/>
 383. Kwaadaardig herseninfarct na vaccinatie met ChAdOx1 nCoV-19: een catastrofale variant van vaccin-geïnduceerde immuungemedieerde trombotische trombocytopenie: <https://pubmed.ncbi.nlm.nih.gov/34341358/>
 384. Acute ischemische beroerte die immuuntrombotische trombocytopenie onthult veroorzaakt door ChAdOx1 nCoV-19-vaccin: impact op rekanalisatiestrategie: <https://pubmed.ncbi.nlm.nih.gov/34175640/>
 385. Door vaccins geïnduceerde immuuntrombotische immuuntrombocytopenie (VITT): een nieuwe klinisch-pathologische entiteit met heterogene klinische presentaties: <https://pubmed.ncbi.nlm.nih.gov/34159588/>
 386. Beeldvorming en hematologische bevindingen bij trombose en trombocytopenie na vaccinatie met ChAdOx1 nCoV-19 (AstraZeneca): <https://pubmed.ncbi.nlm.nih.gov/34402666/>
 387. Auto-immuniteitswortels van trombotische gebeurtenissen na vaccinatie met COVID-19: <https://pubmed.ncbi.nlm.nih.gov/34508917/>
 388. Cerebrale veneuze sinustrombose na vaccinatie: de Britse ervaring: <https://pubmed.ncbi.nlm.nih.gov/34370974/>
 389. Massale cerebrale veneuze trombose en veneus bekkeninfarct als late complicaties van COVID-19: een casusrapport: <https://pubmed.ncbi.nlm.nih.gov/34373991/>
 390. Australische en Nieuw-Zeelandse benadering van de diagnose en behandeling van door vaccins veroorzaakte immuuntrombose en immuuntrombocytopenie: <https://pubmed.ncbi.nlm.nih.gov/34490632/>
 391. Een observationele studie om de prevalentie van trombocytopenie en anti-PF4 / polyanion-antilichamen bij Noorse gezondheidswerkers na COVID-19-vaccinatie te identificeren: <https://pubmed.ncbi.nlm.nih.gov/33909350/>
 392. Acute transverse myelitis (ATM): klinische beoordeling van 43 patiënten met COVID-19-geassocieerde ATM en 3 ernstige bijwerkingen van post-vaccinatie ATM met ChAdOx1 nCoV-19 (AZD1222) vaccin: <https://pubmed.ncbi.nlm.nih.gov/33981305/>
 393. Een geval van acute demyeliniserende polyradiculoneuropathie met bilaterale gezichtsverlamming na ChAdOx1 nCoV-19-vaccin.: <https://pubmed.ncbi.nlm.nih.gov/34272622/>
 394. Trombocytopenie met acute ischemische beroerte en bloeding bij een patiënt die onlangs is gevaccineerd met een adenoviraal vectorgebaseerd COVID-19-vaccin.: <https://pubmed.ncbi.nlm.nih.gov/33877737/>
 395. Voorspelde en waargenomen incidentie van trombo-embolische voorvallen bij Koreanen die zijn gevaccineerd met het ChAdOx1 nCoV-19-vaccin: <https://pubmed.ncbi.nlm.nih.gov/34254476/>
 396. Eerste dosis ChAdOx1- en BNT162b2 COVID-19-vaccins en trombocytopenische, trombo-embolische en hemorragische voorvallen in Schotland: <https://pubmed.ncbi.nlm.nih.gov/34108714/>
 397. ChAdOx1 nCoV-19 vaccin-geassocieerde trombocytopenie: drie gevallen van immuuntrombocytopenie na 107.720 doses ChAdOx1-vaccinatie in Thailand: <https://pubmed.ncbi.nlm.nih.gov/34483267/>
 398. Pulmonary embolism, transient ischemic attack, and thrombocytopenia after Johnson & Johnson COVID-19 vaccine: <https://pubmed.ncbi.nlm.nih.gov/34261635/>
 399. Neurosurgical considerations with respect to decompressive craniectomy for intracerebral hemorrhage after SARS-CoV-2 vaccination in vaccine-induced thrombotic thrombocytopenia-VITT: <https://pubmed.ncbi.nlm.nih.gov/34202817/>
 400. Large hemorrhagic stroke after vaccination against ChAdOx1 nCoV-19: a case report: <https://pubmed.ncbi.nlm.nih.gov/34273119/>
 401. Polyarthralgia and myalgia syndrome after vaccination with ChAdOx1 nCoV-19: <https://pubmed.ncbi.nlm.nih.gov/34463066/>
 402. A rare case of thrombosis and thrombocytopenia of the superior ophthalmic vein after ChAdOx1 nCoV-19 vaccination against SARS-CoV-2: <https://pubmed.ncbi.nlm.nih.gov/34276917/>
 403. Thrombosis and severe acute respiratory syndrome Coronavirus 2 vaccines: vaccine-induced immune thrombotic thrombocytopenia: <https://pubmed.ncbi.nlm.nih.gov/34237213/>
 404. Renal vein thrombosis and pulmonary embolism secondary to vaccine-induced thrombotic immune thrombocytopenia (VITT): <https://pubmed.ncbi.nlm.nih.gov/34268278/>
 405. Limb ischemia and pulmonary artery thrombosis after ChAdOx1 nCoV-19 vaccine (Oxford-AstraZeneca): a case of vaccine-induced immune thrombotic thrombocytopenia: <https://pubmed.ncbi.nlm.nih.gov/33990339/>
 406. Association between ChAdOx1 nCoV-19 vaccination and bleeding episodes: large population-based cohort study: <https://pubmed.ncbi.nlm.nih.gov/34479760/>
 407. Secondary thrombocytopenia after SARS-CoV-2 vaccination: case report of haemorrhage and hematoma after minor oral surgery: <https://pubmed.ncbi.nlm.nih.gov/34314875/>
 408. Venous thromboembolism and mild thrombocytopenia after vaccination with ChAdOx1 nCoV-19: <https://pubmed.ncbi.nlm.nih.gov/34384129/>
 409. Fatal exacerbation of ChAdOx1-nCoV-19-induced thrombotic thrombocytopenia syndrome after successful initial therapy with intravenous immunoglobulins: a rationale for monitoring immunoglobulin G levels: <https://pubmed.ncbi.nlm.nih.gov/34382387/>
 410. A case of ANCA-associated vasculitis after AZD1222 (Oxford-AstraZeneca) SARS-CoV-2 vaccination: victim or causality?: <https://pubmed.ncbi.nlm.nih.gov/34416184/>
 411. Intracerebral hemorrhage associated with vaccine-induced thrombotic thrombocytopenia after ChAdOx1 nCoV-19 vaccination in a pregnant woman: <https://pubmed.ncbi.nlm.nih.gov/34261297/>
 412. Massive cerebral venous thrombosis due to vaccine-induced immune thrombotic thrombocytopenia: <https://pubmed.ncbi.nlm.nih.gov>

/34261296/

413. Nephrotic syndrome after ChAdOx1 nCoV-19 vaccine against SARS-CoV-2: <https://pubmed.ncbi.nlm.nih.gov/34250318/>.
414. A case of vaccine-induced immune-immune thrombotic thrombocytopenia with massive arteriovenous thrombosis: <https://pubmed.ncbi.nlm.nih.gov/34059191/>
415. Cutaneous thrombosis associated with cutaneous necrosis following Oxford-AstraZeneca COVID-19 vaccination: <https://pubmed.ncbi.nlm.nih.gov/34189756/>
416. Thrombocytopenia in an adolescent with sickle cell anemia after COVID-19 vaccination: <https://pubmed.ncbi.nlm.nih.gov/34331506/>
417. Vaccine-induced thrombocytopenia with severe headache: <https://pubmed.ncbi.nlm.nih.gov/34525282/>
418. Myocarditis associated with SARS-CoV-2 mRNA vaccination in children aged 12 to 17 years: stratified analysis of a national database: <https://www.medrxiv.org/content/10.1101/2021.08.30.21262866v1>
419. COVID-19 mRNA vaccination and development of CMR-confirmed myopericarditis: <https://www.medrxiv.org/content/10.1101/2021.09.13.21262182v1.full?s=09>.
420. Severe autoimmune hemolytic anemia after receipt of SARS-CoV-2 mRNA vaccine: <https://onlinelibrary.wiley.com/doi/10.1111/trf.16672>
421. Intravenous injection of coronavirus disease 2019 (COVID-19) mRNA vaccine can induce acute myopericarditis in a mouse model: <https://t.co/j0IEM8cMXI>
422. A report of myocarditis adverse events in the U.S. Vaccine Adverse Event Reporting System. (VAERS) in association with COVID-19 injectable biologics: <https://pubmed.ncbi.nlm.nih.gov/34601006/>
423. This study concludes that: "The vaccine was associated with an excess risk of myocarditis (1 to 5 events per 100,000 persons). The risk of this potentially serious adverse event and of many other serious adverse events increased substantially after SARS-CoV-2 infection": <https://www.nejm.org/doi/full/10.1056/NEJMoa2110475>
424. Bilateral uveitis after inoculation with COVID-19 vaccine: a case report: <https://www.sciencedirect.com/science/article/pii/S1201971221007797>
425. Myocarditis associated with SARS-CoV-2 mRNA vaccination in children aged 12 to 17 years: stratified analysis of a national database: <https://www.medrxiv.org/content/10.1101/2021.08.30.21262866v1>.
426. Immune-mediated hepatitis with the Moderna vaccine is no longer a coincidence but confirmed: <https://www.sciencedirect.com/science/article/pii/S0168827821020936>
427. Extensive investigations revealed consistent pathophysiologic alterations after vaccination with COVID-19 vaccines: <https://www.nature.com/articles/s41421-021-00329-3>
428. Lobar hemorrhage with ventricular rupture shortly after the first dose of an mRNA-based SARS-CoV-2 vaccine: <https://www.ncbi.nlm.nih.gov/labs/pmc/articles/PMC8553377/>
429. Mrna COVID vaccines dramatically increase endothelial inflammatory markers and risk of Acute Coronary Syndrome as measured by PULS cardiac testing: a caution: https://www.ahajournals.org/doi/10.1161/circ.144.suppl_1.10712
430. ChAdOx1 interacts with CAR and PF4 with implications for thrombosis with thrombocytopenia syndrome: <https://www.science.org/doi/10.1126/sciadv.abl8213>
431. Lethal vaccine-induced immune thrombotic immune thrombocytopenia (VITT) following announcement 26.COVID.S: first documented case outside the U.S.: <https://pubmed.ncbi.nlm.nih.gov/34626338/>
432. A prothrombotic thrombocytopenic disorder resembling heparin-induced thrombocytopenia after coronavirus-19 vaccination: <https://europepmc.org/article/PPR/PPR304469435>.
433. VITT (vaccine-induced immune thrombotic thrombocytopenia) after vaccination with ChAdOx1 nCoV-19: <https://pubmed.ncbi.nlm.nih.gov/34731555/>
434. Vaccine-induced immune thrombotic thrombocytopenia (VITT): a new clinicopathologic entity with heterogeneous clinical presentations: <https://pubmed.ncbi.nlm.nih.gov/34159588/>
435. Treatment of acute ischemic stroke associated with ChAdOx1 nCoV-19 vaccine-induced immune thrombotic thrombocytopenia: <https://pubmed.ncbi.nlm.nih.gov/34461442/>
436. Spectrum of neurological complications after COVID-19 vaccination: <https://pubmed.ncbi.nlm.nih.gov/34719776/>.
437. Cerebral venous sinus thrombosis after vaccination: the UK experience: <https://pubmed.ncbi.nlm.nih.gov/34370974/>
438. Cerebral venous vein/venous sinus thrombosis with thrombocytopenia syndrome after COVID-19 vaccination: <https://pubmed.ncbi.nlm.nih.gov/34373413/>
439. Portal vein thrombosis due to vaccine-induced immune thrombotic immune thrombocytopenia (VITT) after Covid vaccination with ChAdOx1 nCoV-19: <https://pubmed.ncbi.nlm.nih.gov/34598301/>
440. Hematuria, a generalized petechial rash and headaches after Oxford AstraZeneca ChAdOx1 nCoV-19 vaccination: <https://pubmed.ncbi.nlm.nih.gov/34620638/>
441. Myocardial infarction and azygos vein thrombosis after vaccination with ChAdOx1 nCoV-19 in a hemodialysis patient: <https://pubmed.ncbi.nlm.nih.gov/34650896/>
442. Takotsubo (stress) cardiomyopathy after vaccination with ChAdOx1 nCoV-19: <https://pubmed.ncbi.nlm.nih.gov/34625447/>
443. Humoral response induced by Prime-Boost vaccination with ChAdOx1 nCoV-19 and BNT162b2 mRNA vaccines in a patient with multiple sclerosis treated with teriflunomide: <https://pubmed.ncbi.nlm.nih.gov/34696248/>
444. Guillain-Barré syndrome after ChAdOx1 nCoV-19 COVID-19 vaccination: a case series: <https://pubmed.ncbi.nlm.nih.gov/34548920/>
445. Refractory vaccine-induced immune thrombotic thrombocytopenia (VITT) treated with delayed therapeutic plasma exchange (TPE): <https://pubmed.ncbi.nlm.nih.gov/34672380/>.
446. Rare case of COVID-19 vaccine-associated intracranial hemorrhage with venous sinus thrombosis: <https://pubmed.ncbi.nlm.nih.gov/34556531/>.
447. Delayed headache after COVID-19 vaccination: a warning sign for vaccine-induced cerebral venous thrombosis: <https://pubmed.ncbi.nlm.nih.gov/34535076/>.
448. Clinical features of vaccine-induced thrombocytopenia and immune thrombosis: <https://pubmed.ncbi.nlm.nih.gov/34379914/>.
449. Predictors of mortality in thrombotic thrombocytopenia after adenoviral COVID-19 vaccination: the FAPIC score: <https://pubmed.ncbi.nlm.nih.gov/34545400/>
450. Ischemic stroke as a presenting feature of immune thrombotic thrombocytopenia induced by ChAdOx1-nCoV-19 vaccination: <https://pubmed.ncbi.nlm.nih.gov/34035134/>
451. In-hospital observational study of neurological disorders in patients recently vaccinated with COVID-19 mRNA vaccines:

<https://pubmed.ncbi.nlm.nih.gov/34688190/>

452. Endovascular treatment for vaccine-induced cerebral venous sinus thrombosis and thrombocytopenia after vaccination with ChAdOx1 nCoV-19: report of three cases: <https://pubmed.ncbi.nlm.nih.gov/34782400/>
453. Cardiovascular, neurological, and pulmonary events after vaccination with BNT162b2, ChAdOx1 nCoV-19, and Ad26.COV2.S vaccines: an analysis of European data: <https://pubmed.ncbi.nlm.nih.gov/34710832/>
454. Cerebral venous thrombosis developing after vaccination. COVID-19: VITT, VATT, TTS and more: <https://pubmed.ncbi.nlm.nih.gov/34695859/>
455. Cerebral venous thrombosis and myeloproliferative neoplasms: a three-center study of 74 consecutive cases: <https://pubmed.ncbi.nlm.nih.gov/34453762/>.
456. Possible triggers of thrombocytopenia and/or hemorrhage by BNT162b2 vaccine, Pfizer-BioNTech: <https://pubmed.ncbi.nlm.nih.gov/34660652/>.
457. Multiple sites of arterial thrombosis in a 35-year-old patient after vaccination with ChAdOx1 (AstraZeneca), which required emergency femoral and carotid surgical thrombectomy: <https://pubmed.ncbi.nlm.nih.gov/34644642/>
458. Case series of vaccine-induced thrombotic thrombocytopenia in a London teaching hospital: <https://pubmed.ncbi.nlm.nih.gov/34694650/>
459. Neuro-ophthalmic complications with thrombocytopenia and thrombosis induced by ChAdOx1 nCoV-19 vaccine: <https://pubmed.ncbi.nlm.nih.gov/34726934/>
460. Thrombotic events after COVID-19 vaccination in over 50 years of age: results of a population-based study in Italy: <https://pubmed.ncbi.nlm.nih.gov/34835237/>
461. Intracerebral hemorrhage associated with vaccine-induced thrombotic thrombocytopenia after ChAdOx1 nCOVID-19 vaccination in a pregnant woman: <https://pubmed.ncbi.nlm.nih.gov/34261297/>
462. Age- and sex-specific incidence of cerebral venous sinus thrombosis associated with Ad26.COV2.S COVID-19 vaccination: <https://pubmed.ncbi.nlm.nih.gov/34724036/>.
463. Genital necrosis with cutaneous thrombosis following vaccination with COVID-19 mRNA: <https://pubmed.ncbi.nlm.nih.gov/34839563/>
464. Cerebral venous sinus thrombosis after mRNA-based COVID-19 vaccination: <https://pubmed.ncbi.nlm.nih.gov/34783932/>.
465. COVID-19 vaccine-induced immune thrombosis with thrombocytopenia thrombosis (VITT) and shades of gray in thrombus formation: <https://pubmed.ncbi.nlm.nih.gov/34624910/>
466. Inflammatory myositis after vaccination with ChAdOx1: <https://pubmed.ncbi.nlm.nih.gov/34585145/>
467. Acute ST-segment elevation myocardial infarction secondary to vaccine-induced immune thrombosis with thrombocytopenia (VITT): <https://pubmed.ncbi.nlm.nih.gov/34580132/>.
468. A rare case of COVID-19 vaccine-induced thrombotic thrombocytopenia (VITT) affecting the venosplanchnic and pulmonary arterial circulation from a UK district general hospital: <https://pubmed.ncbi.nlm.nih.gov/34535492/>
469. COVID-19 vaccine-induced thrombotic thrombocytopenia: a case series: <https://pubmed.ncbi.nlm.nih.gov/34527501/>
470. Thrombosis with thrombocytopenia syndrome (TTS) after vaccination with AstraZeneca ChAdOx1 nCoV-19 (AZD1222) COVID-19: a risk-benefit analysis for persons <60% risk-benefit analysis for people <60 years in Australia: <https://pubmed.ncbi.nlm.nih.gov/34272095/>
471. Immune thrombocytopenia after immunization with Vaxzevria ChadOx1-S vaccine (AstraZeneca), Victoria, Australia: <https://pubmed.ncbi.nlm.nih.gov/34756770/>
472. Characteristics and outcomes of patients with cerebral venous sinus thrombosis in thrombotic immune thrombocytopenia induced by SARS-CoV-2 vaccine: <https://jamanetwork.com/journals/jamaneurology/fullarticle/2784622>
473. Case study of thrombosis and thrombocytopenia syndrome after administration of the AstraZeneca COVID-19 vaccine: <https://pubmed.ncbi.nlm.nih.gov/34781321/>
474. Thrombosis with Thrombocytopenia Syndrome Associated with COVID-19 Vaccines: <https://pubmed.ncbi.nlm.nih.gov/34062319/>
475. Cerebral venous sinus thrombosis following vaccination with ChAdOx1: the first case of definite thrombosis with thrombocytopenia syndrome in India: <https://pubmed.ncbi.nlm.nih.gov/34706921/>
476. COVID-19 vaccine-associated thrombosis with thrombocytopenia syndrome (TTS): systematic review and post hoc analysis: <https://pubmed.ncbi.nlm.nih.gov/34698582/>.
477. Case report of immune thrombocytopenia after vaccination with ChAdOx1 nCoV-19: <https://pubmed.ncbi.nlm.nih.gov/34751013/>.
478. Acute transverse myelitis after COVID-19 vaccination: <https://pubmed.ncbi.nlm.nih.gov/34684047/>.
479. Concerns for adverse effects of thrombocytopenia and thrombosis after adenovirus-vectored COVID-19 vaccination: <https://pubmed.ncbi.nlm.nih.gov/34541935/>
480. Major hemorrhagic stroke after ChAdOx1 nCoV-19 vaccination: a case report: <https://pubmed.ncbi.nlm.nih.gov/34273119/>
481. Cerebral venous sinus thrombosis after COVID-19 vaccination: neurologic and radiologic management: <https://pubmed.ncbi.nlm.nih.gov/34327553/>.
482. Thrombocytopenia with acute ischemic stroke and hemorrhage in a patient recently vaccinated with an adenoviral vector-based COVID-19 vaccine: <https://pubmed.ncbi.nlm.nih.gov/33877737/>
483. Intracerebral hemorrhage and thrombocytopenia after AstraZeneca COVID-19 vaccine: clinical and diagnostic challenges of vaccine-induced thrombotic thrombocytopenia: <https://pubmed.ncbi.nlm.nih.gov/34646685/>
484. Minimal change disease with severe acute kidney injury after Oxford-AstraZeneca COVID-19 vaccine: case report: <https://pubmed.ncbi.nlm.nih.gov/34242687/>.
485. Case report: cerebral sinus vein thrombosis in two patients with AstraZeneca SARS-CoV-2 vaccine: <https://pubmed.ncbi.nlm.nih.gov/34609603/>
486. Case report: Pityriasis rosea-like rash after vaccination with COVID-19: <https://pubmed.ncbi.nlm.nih.gov/34557507/>
487. Extensive longitudinal transverse myelitis after ChAdOx1 nCoV-19 vaccine: case report: <https://pubmed.ncbi.nlm.nih.gov/34641797/>.
488. Acute eosinophilic pneumonia associated with anti-COVID-19 vaccine AZD1222: <https://pubmed.ncbi.nlm.nih.gov/34812326/>.
489. Thrombocytopenia, including immune thrombocytopenia after receiving COVID-19 mRNA vaccines reported to the Vaccine Adverse Event Reporting System (VAERS): <https://pubmed.ncbi.nlm.nih.gov/34006408/>
490. A case of ANCA-associated vasculitis after AZD1222 (Oxford-AstraZeneca) SARS-CoV-2 vaccination: victim or causality?: <https://pubmed.ncbi.nlm.nih.gov/34416184/>
491. Vaccine-induced immune thrombosis and thrombocytopenia syndrome after adenovirus-vectored severe acute respiratory syndrome coronavirus 2 vaccination: a new hypothesis on mechanisms and implications for future vaccine development: <https://pubmed.ncbi.nlm.nih.gov/34664303/>.

492. Thrombosis in peripheral artery disease and thrombotic thrombocytopenia following adenoviral COVID-19 vaccination: <https://pubmed.ncbi.nlm.nih.gov/34649281/>.
493. Newly diagnosed immune thrombocytopenia in a pregnant patient after coronavirus disease 2019 vaccination: <https://pubmed.ncbi.nlm.nih.gov/34420249/>
494. Cerebral venous sinus thrombosis and thrombotic events after vector-based COVID-19 vaccines: systematic review and meta-analysis: <https://pubmed.ncbi.nlm.nih.gov/34610990/>.
495. Sweet's syndrome after Oxford-AstraZeneca COVID-19 vaccine (AZD1222) in an elderly woman: <https://pubmed.ncbi.nlm.nih.gov/34590397/>
496. Sudden sensorineural hearing loss after COVID-19 vaccination: <https://pubmed.ncbi.nlm.nih.gov/34670143/>.
497. Prevalence of serious adverse events among health care professionals after receiving the first dose of ChAdOx1 nCoV-19 coronavirus vaccine (Covishield) in Togo, March 2021: <https://pubmed.ncbi.nlm.nih.gov/34819146/>.
498. Acute hemichorea-hemiballismus after COVID-19 (AZD1222) vaccination: <https://pubmed.ncbi.nlm.nih.gov/34581453/>
499. Recurrence of alopecia areata after covid-19 vaccination: a report of three cases in Italy: <https://pubmed.ncbi.nlm.nih.gov/34741583/>
500. Shingles-like skin lesion after vaccination with AstraZeneca for COVID-19: a case report: <https://pubmed.ncbi.nlm.nih.gov/34631069/>
501. Thrombosis after COVID-19 vaccination: possible link to ACE pathways: <https://pubmed.ncbi.nlm.nih.gov/34479129/>
502. Thrombocytopenia in an adolescent with sickle cell anemia after COVID-19 vaccination: <https://pubmed.ncbi.nlm.nih.gov/34331506/>
503. Leukocytoclastic vasculitis as a cutaneous manifestation of ChAdOx1 corona virus vaccine nCoV-19 (recombinant): <https://pubmed.ncbi.nlm.nih.gov/34546608/>
504. Abdominal pain and bilateral adrenal hemorrhage from immune thrombotic thrombocytopenia induced by COVID-19 vaccine: <https://pubmed.ncbi.nlm.nih.gov/34546343/>
505. Longitudinally extensive cervical myelitis after vaccination with inactivated virus based COVID-19 vaccine: <https://pubmed.ncbi.nlm.nih.gov/34849183/>
506. Induction of cutaneous leukocytoclastic vasculitis after ChAdOx1 nCoV-19 vaccine: <https://pubmed.ncbi.nlm.nih.gov/34853744/>.
507. A case of toxic epidermal necrolysis after vaccination with ChAdOx1 nCoV-19 (AZD1222): <https://pubmed.ncbi.nlm.nih.gov/34751429/>.
508. Ocular adverse events following COVID-19 vaccination: <https://pubmed.ncbi.nlm.nih.gov/34559576/>
509. Depression after ChAdOx1-S / nCoV-19 vaccination: <https://pubmed.ncbi.nlm.nih.gov/34608345/>.
510. Venous thromboembolism and mild thrombocytopenia after ChAdOx1 nCoV-19 vaccination: <https://pubmed.ncbi.nlm.nih.gov/34384129/>.
511. Recurrent ANCA-associated vasculitis after Oxford AstraZeneca ChAdOx1-S COVID-19 vaccination: a case series of two patients: <https://pubmed.ncbi.nlm.nih.gov/34755433/>
512. Major artery thrombosis and vaccination against ChAdOx1 nCov-19: <https://pubmed.ncbi.nlm.nih.gov/34839830/>
513. Rare case of contralateral supraclavicular lymphadenopathy after vaccination with COVID-19: computed tomography and ultrasound findings: <https://pubmed.ncbi.nlm.nih.gov/34667486/>
514. Cutaneous lymphocytic vasculitis after administration of the second dose of AZD1222 (Oxford-AstraZeneca) Severe acute respiratory syndrome Coronavirus 2 vaccine: chance or causality: <https://pubmed.ncbi.nlm.nih.gov/34726187/>.
515. Pancreas allograft rejection after ChAdOx1 nCoV-19 vaccine: <https://pubmed.ncbi.nlm.nih.gov/34781027/>
516. Understanding the risk of thrombosis with thrombocytopenia syndrome following Ad26.COVS.2 vaccination: <https://pubmed.ncbi.nlm.nih.gov/34595694/>
517. Cutaneous adverse reactions of 35,229 doses of COVID-19 Sinovac and AstraZeneca vaccine COVID-19: a prospective cohort study in health care workers: <https://pubmed.ncbi.nlm.nih.gov/34661934/>
518. Comments on thrombosis after vaccination: spike protein leader sequence could be responsible for thrombosis and antibody-mediated thrombocytopenia: <https://pubmed.ncbi.nlm.nih.gov/34788138/>
519. Eosinophilic dermatosis after AstraZeneca COVID-19 vaccination: <https://pubmed.ncbi.nlm.nih.gov/34753210/>.
520. Severe immune thrombocytopenia following COVID-19 vaccination: report of four cases and review of the literature: <https://pubmed.ncbi.nlm.nih.gov/34653943/>.
521. Relapse of immune thrombocytopenia after COVID-19 vaccination: <https://pubmed.ncbi.nlm.nih.gov/34591991/>
522. Thrombosis in pre- and post-vaccination phase of COVID-19; <https://pubmed.ncbi.nlm.nih.gov/34650382/>
523. A look at the role of postmortem immunohistochemistry in understanding the inflammatory pathophysiology of COVID-19 disease and vaccine-related thrombotic adverse events: a narrative review: <https://pubmed.ncbi.nlm.nih.gov/34769454/>
524. COVID-19 vaccine in patients with hypercoagulability disorders: a clinical perspective: <https://pubmed.ncbi.nlm.nih.gov/34786893/>
525. Vaccine-associated thrombocytopenia and thrombosis: venous endotheliopathy leading to combined venous micro-macrothrombosis: <https://pubmed.ncbi.nlm.nih.gov/34833382/>
526. Thrombosis and thrombocytopenia syndrome causing isolated symptomatic carotid occlusion after COVID-19 Ad26.COVS.2 vaccine (Janssen): <https://pubmed.ncbi.nlm.nih.gov/34670287/>
527. An unusual presentation of acute deep vein thrombosis after Modern COVID-19 vaccine: case report: <https://pubmed.ncbi.nlm.nih.gov/34790811/>
528. Immediate high-dose intravenous immunoglobulins followed by direct treatment with thrombin inhibitors is crucial for survival in vaccine-induced immune thrombotic thrombocytopenia Sars-Covid-19-vector adenoviral VITT with venous thrombosis of the cerebral sinus and portal vein: <https://pubmed.ncbi.nlm.nih.gov/34023956/>.
529. Thrombosis formation after COVID-19 vaccination immunologic aspects: review article: <https://pubmed.ncbi.nlm.nih.gov/34629931/>
530. Imaging and hematologic findings in thrombosis and thrombocytopenia after vaccination with ChAdOx1 nCoV-19 (AstraZeneca): <https://pubmed.ncbi.nlm.nih.gov/34402666/>
531. Spectrum of neuroimaging findings in post-CoVID-19 vaccination: a case series and review of the literature: <https://pubmed.ncbi.nlm.nih.gov/34842783/>
532. Cerebral venous sinus thrombosis, pulmonary embolism, and thrombocytopenia after COVID-19 vaccination in a Taiwanese man: a case report and review of the literature: <https://pubmed.ncbi.nlm.nih.gov/34630307/>
533. Fatal cerebral venous sinus thrombosis after COVID-19 vaccination: <https://pubmed.ncbi.nlm.nih.gov/33983464/>
534. Autoimmune roots of thrombotic events after COVID-19 vaccination: <https://pubmed.ncbi.nlm.nih.gov/34508917/>.
535. New portal vein thrombosis in cirrhosis: is thrombophilia exacerbated by vaccine or COVID-19: [https://www.jcehepatology.com/article/S0973-6883\(21\)00545-4/fulltext](https://www.jcehepatology.com/article/S0973-6883(21)00545-4/fulltext).
536. Images of immune thrombotic thrombocytopenia induced by Oxford / AstraZeneca® COVID-19 vaccine: <https://pubmed.ncbi.nlm.nih.gov>

- /33962903/.
537. Cerebral venous sinus thrombosis after vaccination with COVID-19 mRNA of BNT162b2: <https://pubmed.ncbi.nlm.nih.gov/34796065/>.
538. Increased risk of urticaria/angioedema after BNT162b2 mRNA COVID-19 vaccination in health care workers taking ACE inhibitors: <https://pubmed.ncbi.nlm.nih.gov/34579248/>
539. A case of unusual mild clinical presentation of COVID-19 vaccine-induced immune thrombotic thrombocytopenia with splanchnic vein thrombosis: <https://pubmed.ncbi.nlm.nih.gov/34843991/>
540. Cerebral venous sinus thrombosis following vaccination with Pfizer-BioNTech COVID-19 (BNT162b2): <https://pubmed.ncbi.nlm.nih.gov/34595867/>
541. A case of idiopathic thrombocytopenic purpura after a booster dose of COVID-19 BNT162b2 vaccine (Pfizer-Biontech): <https://pubmed.ncbi.nlm.nih.gov/34820240/>
542. Vaccine-induced immune thrombotic immune thrombocytopenia (VITT): targeting pathologic mechanisms with Bruton's tyrosine kinase inhibitors: <https://pubmed.ncbi.nlm.nih.gov/33851389/>
543. Thrombotic thrombocytopenic purpura after vaccination with Ad26.COV2-S: <https://pubmed.ncbi.nlm.nih.gov/33980419/>
544. Thromboembolic events in younger females exposed to Pfizer-BioNTech or Moderna COVID-19 vaccines: <https://pubmed.ncbi.nlm.nih.gov/34264151/>
545. Potential risk of thrombotic events after COVID-19 vaccination with Oxford-AstraZeneca in women receiving estrogen: <https://pubmed.ncbi.nlm.nih.gov/34734086/>
546. Thrombosis after adenovirus-vectored COVID-19 vaccination: a concern for underlying disease: <https://pubmed.ncbi.nlm.nih.gov/34755555/>
547. Adenovirus interactions with platelets and coagulation and vaccine-induced immune thrombotic thrombocytopenia syndrome: <https://pubmed.ncbi.nlm.nih.gov/34407607/>
548. Thrombotic thrombocytopenic purpura: a new threat after COVID bnt162b2 vaccine: <https://pubmed.ncbi.nlm.nih.gov/34264514/>.
549. Unusual site of deep vein thrombosis after vaccination against coronavirus mRNA-2019 coronavirus disease (COVID-19): <https://pubmed.ncbi.nlm.nih.gov/34840204/>
550. Neurological side effects of SARS-CoV-2 vaccines: <https://pubmed.ncbi.nlm.nih.gov/34750810/>
551. Coagulopathies after SARS-CoV-2 vaccination may derive from a combined effect of SARS-CoV-2 spike protein and adenovirus vector-activated signaling pathways: <https://pubmed.ncbi.nlm.nih.gov/34639132/>
552. Isolated pulmonary embolism after COVID vaccination: 2 case reports and a review of acute pulmonary embolism complications and follow-up: <https://pubmed.ncbi.nlm.nih.gov/34804412/>
553. Central retinal vein occlusion after vaccination with SARS-CoV-2 mRNA: case report: <https://pubmed.ncbi.nlm.nih.gov/34571653/>.
554. Complicated case report of long-term vaccine-induced thrombotic immune thrombocytopenia A: <https://pubmed.ncbi.nlm.nih.gov/34835275/>.
555. Deep venous thrombosis after vaccination with Ad26.COV2.S in adult males: <https://pubmed.ncbi.nlm.nih.gov/34659839/>.
556. Neurological autoimmune diseases after SARS-CoV-2 vaccination: a case series: <https://pubmed.ncbi.nlm.nih.gov/34668274/>.
557. Severe autoimmune hemolytic autoimmune anemia after receiving SARS-CoV-2 mRNA vaccine: <https://pubmed.ncbi.nlm.nih.gov/34549821/>
558. Occurrence of COVID-19 variants among recipients of ChAdOx1 nCoV-19 vaccine (recombinant): <https://pubmed.ncbi.nlm.nih.gov/34528522/>
559. Prevalence of thrombocytopenia, anti-platelet factor 4 antibodies, and elevated D-dimer in Thais after vaccination with ChAdOx1 nCoV-19: <https://pubmed.ncbi.nlm.nih.gov/34568726/>
560. Epidemiology of acute myocarditis/pericarditis in Hong Kong adolescents after co-vaccination: <https://academic.oup.com/cid/advance-article-abstract/doi/10.1093/cid/ciab989/6445179>.
561. Myocarditis after 2019 coronavirus disease mRNA vaccine: a case series and determination of incidence rate: <https://academic.oup.com/cid/advance-article/doi/10.1093/cid/ciab926/6420408>
562. Myocarditis and pericarditis after COVID-19 vaccination: inequalities in age and vaccine types: <https://www.mdpi.com/2075-4426/11/11/1106>
563. Epidemiology and clinical features of myocarditis/pericarditis before the introduction of COVID-19 mRNA vaccine in Korean children: a multicenter study: <https://pubmed.ncbi.nlm.nih.gov/34402230/>
564. Shedding light on post-vaccination myocarditis and pericarditis in COVID-19 and non-COVID-19 vaccine recipients: <https://pubmed.ncbi.nlm.nih.gov/34696294/>
565. Myocarditis Following mRNA COVID-19 Vaccine: https://journals.lww.com/pec-online/Abstract/2021/11000/Myocarditis_Following_mRNA_COVID_19_Vaccine.9.aspx.
566. Myocarditis following BNT162b2 mRNA Covid-19 mRNA vaccine in Israel: <https://pubmed.ncbi.nlm.nih.gov/34614328/>.
567. Myocarditis, pericarditis, and cardiomyopathy following COVID-19 vaccination: [https://www.heartlungcirc.org/article/S1443-9506\(21\)01156-2/fulltext](https://www.heartlungcirc.org/article/S1443-9506(21)01156-2/fulltext)
568. Myocarditis and other cardiovascular complications of COVID-19 mRNA-based COVID-19 vaccines: <https://pubmed.ncbi.nlm.nih.gov/34277198/>
569. Possible Association Between COVID-19 Vaccine and Myocarditis: Clinical and CMR Findings: <https://pubmed.ncbi.nlm.nih.gov/34246586/>
570. Hypersensitivity Myocarditis and COVID-19 Vaccines: <https://pubmed.ncbi.nlm.nih.gov/34856634/>.
571. Severe myocarditis associated with COVID-19 vaccine: zebra or unicorn?: [https://www.internationaljournalofcardiology.com/article/S0167-5273\(21\)01477-7/fulltext](https://www.internationaljournalofcardiology.com/article/S0167-5273(21)01477-7/fulltext).
572. Acute myocardial infarction and myocarditis after COVID-19 vaccination: <https://www.ncbi.nlm.nih.gov/labs/pmc/articles/PMC8522388/>
573. Myocarditis after Covid-19 vaccination in a large healthcare organization: <https://www.nejm.org/doi/10.1056/NEJMoa2110737>
574. Association of myocarditis with COVID-19 messenger RNA BNT162b2 vaccine in a case series of children: <https://jamanetwork.com/journals/jamacardiology/fullarticle/2783052>
575. Clinical suspicion of myocarditis temporally related to COVID-19 vaccination in adolescents and young adults: https://www.ahajournals.org/doi/abs/10.1161/CIRCULATIONAHA.121.056583?url_ver=Z39.88-2003&rfr_id=ori:rid:crossref.org&rfr_dat=cr_pub%20%20pubmed
576. STEMI mimicry: focal myocarditis in an adolescent patient after COVID-19 mRNA vaccination.: <https://pubmed.ncbi.nlm.nih.gov/34756746/>
577. Myocarditis and pericarditis in association with COVID-19 mRNA vaccination: cases from a regional pharmacovigilance center: <https://www.ncbi.nlm.nih.gov/labs/pmc/articles/PMC8587334/>
578. Myocarditis after COVID-19 mRNA vaccines: <https://pubmed.ncbi.nlm.nih.gov/34546329/>.
579. Patients with acute myocarditis after COVID-19 mRNA vaccination.: <https://jamanetwork.com/journals/jamacardiology/fullarticle/2781602>.
580. Myocarditis after COVID-19 vaccination: a case series: <https://www.sciencedirect.com/science/article/pii/S0264410X21011725?via%3Dihub>.
581. Myocarditis associated with COVID-19 vaccination in adolescents: <https://publications.aap.org/pediatrics/article/148/5/e2021053427/181357>

582. Myocarditis findings on cardiac magnetic resonance imaging after vaccination with COVID-19 mRNA in adolescents.: <https://pubmed.ncbi.nlm.nih.gov/34704459/>
583. Myocarditis after COVID-19 vaccination: magnetic resonance imaging study: <https://academic.oup.com/ehjcmimaging/advance-article/doi/10.1093/ehjci/jeab230/6421640>.
584. Acute myocarditis after administration of the second dose of BNT162b2 COVID-19 vaccine: <https://www.ncbi.nlm.nih.gov/labs/pmc/articles/PMC8599115/>
585. Myocarditis after COVID-19 vaccination: <https://www.sciencedirect.com/science/article/pii/S2352906721001603>
586. Case report: probable myocarditis after Covid-19 mRNA vaccine in a patient with arrhythmogenic left ventricular cardiomyopathy: <https://pubmed.ncbi.nlm.nih.gov/34712717/>.
587. Acute myocarditis after administration of BNT162b2 vaccine against COVID-19: <https://www.revespcardiol.org/en-linkresolver-acute-myocarditis-after-administration-bnt162b2-S188558572100133X>.
588. Myocarditis associated with COVID-19 mRNA vaccination: <https://pubs.rsna.org/doi/10.1148/radiol.2021211430>
589. Acute myocarditis after COVID-19 vaccination: a case report: <https://www.sciencedirect.com/science/article/pii/S0248866321007098>
590. Acute myopericarditis after COVID-19 vaccination in adolescents.: <https://pubmed.ncbi.nlm.nih.gov/34589238/>.
591. Perimyocarditis in adolescents after Pfizer-BioNTech COVID-19 vaccination: <https://academic.oup.com/jpids/article/10/10/962/6329543>.
592. Acute myocarditis associated with anti-COVID-19 vaccination: <https://ecevr.org/DOIx.php?id=10.7774/cevr.2021.10.2.196>.
593. Myocarditis associated with COVID-19 vaccination: echocardiographic, cardiac CT, and MRI findings.: <https://pubmed.ncbi.nlm.nih.gov/34428917/>.
594. Acute symptomatic myocarditis in 7 adolescents after Pfizer-BioNTech COVID-19 vaccination.: <https://pubmed.ncbi.nlm.nih.gov/34088762/>.
595. Myocarditis and pericarditis in adolescents after first and second doses of COVID-19 mRNA vaccines.: <https://academic.oup.com/ehjqcco/advance-article/doi/10.1093/ehjqcco/qcab090/6442104>.
596. COVID 19 vaccine for adolescents. Concern for myocarditis and pericarditis: <https://www.mdpi.com/2036-7503/13/3/61>.
597. Cardiac imaging of acute myocarditis after vaccination with COVID-19 mRNA: <https://pubmed.ncbi.nlm.nih.gov/34402228/>
598. Myocarditis temporally associated with COVID-19 vaccination: <https://pubmed.ncbi.nlm.nih.gov/34133885/>
599. Acute myocardial injury after COVID-19 vaccination: a case report and review of current evidence from the vaccine adverse event reporting system database: <https://pubmed.ncbi.nlm.nih.gov/34219532/>
600. Acute myocarditis associated with COVID-19 vaccination: report of a case: <https://www.ncbi.nlm.nih.gov/labs/pmc/articles/PMC8639400/>
601. Myocarditis following vaccination with COVID-19 messenger RNA: a Japanese case series: <https://pubmed.ncbi.nlm.nih.gov/34840235/>.
602. Myocarditis in the setting of a recent COVID-19 vaccination: <https://pubmed.ncbi.nlm.nih.gov/34712497/>.
603. Acute myocarditis after a second dose of COVID-19 mRNA vaccine: report of two cases: [https://www.clinicalimaging.org/article/S0899-7071\(21\)00265-5/fulltext](https://www.clinicalimaging.org/article/S0899-7071(21)00265-5/fulltext).
604. Prevalence of thrombocytopenia, antiplatelet factor 4 antibodies, and elevated D-dimer in Thais after vaccination with ChAdOx1 nCoV-19: <https://pubmed.ncbi.nlm.nih.gov/34568726/>
605. Epidemiology of acute myocarditis/pericarditis in Hong Kong adolescents after co-vaccination: <https://academic.oup.com/cid/advance-article-abstract/doi/10.1093/cid/ciab989/6445179>
606. Myocarditis after 2019 coronavirus disease mRNA vaccine: a case series and incidence rate determination: <https://academic.oup.com/cid/advance-article/doi/10.1093/cid/ciab926/6420408>.
607. Myocarditis and pericarditis after COVID-19 vaccination: inequalities in age and vaccine types: <https://www.mdpi.com/2075-4426/11/11/1106>
608. Epidemiology and clinical features of myocarditis/pericarditis before the introduction of COVID-19 mRNA vaccine in Korean children: a multicenter study: <https://pubmed.ncbi.nlm.nih.gov/34402230/>
609. Shedding light on post-vaccination myocarditis and pericarditis in COVID-19 and non-COVID-19 vaccine recipients: <https://pubmed.ncbi.nlm.nih.gov/34696294/>
610. Diffuse prothrombotic syndrome after administration of ChAdOx1 nCoV-19 vaccine: case report: <https://pubmed.ncbi.nlm.nih.gov/34615534/>
611. Three cases of acute venous thromboembolism in women after coronavirus 2019 vaccination: <https://pubmed.ncbi.nlm.nih.gov/34352418/>
612. Clinical and biological features of cerebral venous sinus thrombosis after vaccination with ChAdOx1 nCoV-19; <https://jnnp.bmj.com/content/early/2021/09/29/jnnp-2021-327340>.
613. COV2-S vaccination may reveal hereditary thrombophilia: massive cerebral venous sinus thrombosis in a young man with normal platelet count: <https://pubmed.ncbi.nlm.nih.gov/34632750/>
614. Post-mortem findings in vaccine-induced thrombotic thrombocytopenia: <https://haematologica.org/article/view/haematol.2021.279075>
615. COVID-19 vaccine-induced thrombosis: <https://pubmed.ncbi.nlm.nih.gov/34802488/>.
616. Inflammation and platelet activation after COVID-19 vaccines: possible mechanisms behind vaccine-induced immune thrombocytopenia and thrombosis: <https://pubmed.ncbi.nlm.nih.gov/34887867/>.
617. Anaphylactoid reaction and coronary thrombosis related to COVID-19 mRNA vaccine: <https://pubmed.ncbi.nlm.nih.gov/34863404/>.
618. Vaccine-induced cerebral venous thrombosis and thrombocytopenia. Oxford-AstraZeneca COVID-19: a missed opportunity for rapid return on experience: <https://www.sciencedirect.com/science/article/pii/S235255682100093X>
619. Occurrence of splenic infarction due to arterial thrombosis after vaccination with COVID-19: <https://pubmed.ncbi.nlm.nih.gov/34876440/>
620. Deep venous thrombosis more than two weeks after COVID-19 vaccination: <https://pubmed.ncbi.nlm.nih.gov/33928773/>
621. Case report: Take a second look: Cerebral venous thrombosis related to Covid-19 vaccination and thrombotic thrombocytopenia syndrome: <https://pubmed.ncbi.nlm.nih.gov/34880826/>
622. Information on ChAdOx1 nCoV-19 vaccine-induced immune-mediated thrombotic thrombocytopenia: <https://pubmed.ncbi.nlm.nih.gov/34587242/>
623. Change in blood viscosity after COVID-19 vaccination: estimation for persons with underlying metabolic syndrome: <https://pubmed.ncbi.nlm.nih.gov/34868465/>
624. Management of a patient with a rare congenital limb malformation syndrome after SARS-CoV-2 vaccine-induced thrombosis and thrombocytopenia (VITT): <https://pubmed.ncbi.nlm.nih.gov/34097311/>
625. Bilateral thalamic stroke: a case of COVID-19 (VITT) vaccine-induced immune thrombotic thrombocytopenia or a coincidence due to underlying risk factors: <https://pubmed.ncbi.nlm.nih.gov/34820232/>.
626. Thrombocytopenia and splanchnic thrombosis after vaccination with Ad26.COV2.S successfully treated with transjugular intrahepatic intrahepatic portosystemic shunt and thrombectomy: <https://onlinelibrary.wiley.com/doi/10.1002/ajh.26258>
627. Incidence of acute ischemic stroke after coronavirus vaccination in Indonesia: case series: <https://pubmed.ncbi.nlm.nih.gov/34579636/>

628. Successful treatment of vaccine-induced immune thrombotic thrombocytopenia in a 26-year-old female patient: <https://pubmed.ncbi.nlm.nih.gov/34614491/>
629. Case report: vaccine-induced immune thrombotic thrombocytopenia in a patient with pancreatic cancer after vaccination with messenger RNA-1273: <https://pubmed.ncbi.nlm.nih.gov/34790684/>
630. Idiopathic idiopathic external jugular vein thrombophlebitis after coronavirus disease vaccination (COVID-19): <https://pubmed.ncbi.nlm.nih.gov/33624509/>.
631. Squamous cell carcinoma of the lung with hemoptysis following vaccination with tozinameran (BNT162b2, Pfizer-BioNTech): <https://pubmed.ncbi.nlm.nih.gov/34612003/>
632. Vaccine-induced thrombotic thrombocytopenia after Ad26.COV2.S vaccination in a man presenting as acute venous thromboembolism: <https://pubmed.ncbi.nlm.nih.gov/34096082/>
633. Myocarditis associated with COVID-19 vaccination in three adolescent boys: <https://pubmed.ncbi.nlm.nih.gov/34851078/>.
634. Cardiovascular magnetic resonance findings in young adult patients with acute myocarditis after COVID-19 mRNA vaccination: a case series: <https://pubmed.ncbi.nlm.nih.gov/34496880/>
635. Perimyocarditis after vaccination with COVID-19: <https://pubmed.ncbi.nlm.nih.gov/34866957/>
636. Epidemiology of acute myocarditis/pericarditis in Hong Kong adolescents after co-vaccination: <https://pubmed.ncbi.nlm.nih.gov/34849657/>.
637. Myocarditis-induced sudden death after BNT162b2 COVID-19 mRNA vaccination in Korea: case report focusing on histopathological findings: <https://pubmed.ncbi.nlm.nih.gov/34664804/>
638. Acute myocarditis after vaccination with COVID-19 mRNA in adults aged 18 years or older: <https://pubmed.ncbi.nlm.nih.gov/34605853/>
639. Recurrence of acute myocarditis temporally associated with receipt of the 2019 coronavirus mRNA disease vaccine (COVID-19) in an adolescent male: <https://pubmed.ncbi.nlm.nih.gov/34166671/>
640. Young male with myocarditis after mRNA-1273 coronavirus disease-2019 (COVID-19) mRNA vaccination: <https://pubmed.ncbi.nlm.nih.gov/34744118/>
641. Acute myocarditis after SARS-CoV-2 vaccination in a 24-year-old male: <https://pubmed.ncbi.nlm.nih.gov/34334935/>.
642. Ga-DOTATOC digital PET images of inflammatory cell infiltrates in myocarditis after vaccination with COVID-19: <https://pubmed.ncbi.nlm.nih.gov/34746968/>
643. Occurrence of acute infarct-like myocarditis after vaccination with COVID-19: just an accidental coincidence or rather a vaccination-associated autoimmune myocarditis?": <https://pubmed.ncbi.nlm.nih.gov/34333695/>.
644. Self-limited myocarditis presenting with chest pain and ST-segment elevation in adolescents after vaccination with BNT162b2 mRNA vaccine: <https://pubmed.ncbi.nlm.nih.gov/34180390/>
645. Myocarditis Following Immunization with COVID-19 mRNA Vaccines in Members of the U.S. Military: <https://pubmed.ncbi.nlm.nih.gov/34185045/>
646. Myocarditis after BNT162b2 vaccination in a healthy male: <https://pubmed.ncbi.nlm.nih.gov/34229940/>
647. Myopericarditis in a previously healthy adolescent male after COVID-19 vaccination: Case report: <https://pubmed.ncbi.nlm.nih.gov/34133825/>
648. Acute myocarditis after SARS-CoV-2 mRNA-1273 mRNA vaccination: <https://pubmed.ncbi.nlm.nih.gov/34308326/>.
649. Chest pain with abnormal electrocardiogram redevelopment after injection of COVID-19 vaccine manufactured by Moderna: <https://pubmed.ncbi.nlm.nih.gov/34866106/>
650. Biopsy-proven lymphocytic myocarditis after first vaccination with COVID-19 mRNA in a 40-year-old man: case report: <https://pubmed.ncbi.nlm.nih.gov/34487236/>
651. Multimodality imaging and histopathology in a young man presenting with fulminant lymphocytic myocarditis and cardiogenic shock after vaccination with mRNA-1273: <https://pubmed.ncbi.nlm.nih.gov/34848416/>
652. Report of a case of myopericarditis after vaccination with BNT162b2 COVID-19 mRNA in a young Korean male: <https://pubmed.ncbi.nlm.nih.gov/34636504/>
653. Acute myocarditis after Comirnaty vaccination in a healthy male with previous SARS-CoV-2 infection: <https://pubmed.ncbi.nlm.nih.gov/34367386/>
654. Acute myocarditis in a young adult two days after vaccination with Pfizer: <https://pubmed.ncbi.nlm.nih.gov/34709227/>
655. Case report: acute fulminant myocarditis and cardiogenic shock after messenger RNA coronavirus vaccination in 2019 requiring extracorporeal cardiopulmonary resuscitation: <https://pubmed.ncbi.nlm.nih.gov/34778411/>
656. Acute myocarditis after 2019 coronavirus disease vaccination: <https://pubmed.ncbi.nlm.nih.gov/34734821/>
657. A series of patients with myocarditis after vaccination against SARS-CoV-2 with mRNA-1279 and BNT162b2: <https://pubmed.ncbi.nlm.nih.gov/34246585/>
658. Myopericarditis after Pfizer messenger ribonucleic acid coronavirus disease vaccine in adolescents: <https://pubmed.ncbi.nlm.nih.gov/34228985/>
659. Post-vaccination multisystem inflammatory syndrome in adults without evidence of prior SARS-CoV-2 infection: <https://pubmed.ncbi.nlm.nih.gov/34852213/>
660. Acute myocarditis defined after vaccination with 2019 mRNA of coronavirus disease: <https://pubmed.ncbi.nlm.nih.gov/34866122/>
661. Biventricular systolic dysfunction in acute myocarditis after SARS-CoV-2 mRNA-1273 vaccination: <https://pubmed.ncbi.nlm.nih.gov/34601566/>
662. Myocarditis following COVID-19 vaccination: MRI study: <https://pubmed.ncbi.nlm.nih.gov/34739045/>.
663. Acute myocarditis after COVID-19 vaccination: case report: https://docs.google.com/document/d/1Hc4bh_qNbZ7UVm5BLxkRdMPnnI9zcCsI/e
664. Association of myocarditis with COVID-19 messenger RNA BNT162b2 vaccine COVID-19 in a case series of children: <https://pubmed.ncbi.nlm.nih.gov/34374740/>
665. Clinical suspicion of myocarditis temporally related to COVID-19 vaccination in adolescents and young adults: <https://pubmed.ncbi.nlm.nih.gov/34865500/>
666. Myocarditis following vaccination with Covid-19 in a large healthcare organization: <https://pubmed.ncbi.nlm.nih.gov/34614329/>
667. AstraZeneca COVID-19 vaccine and Guillain-Barré syndrome in Tasmania: a causal link: <https://pubmed.ncbi.nlm.nih.gov/34560365/>
668. COVID-19, Guillain-Barré and vaccineA dangerous mix: <https://pubmed.ncbi.nlm.nih.gov/34108736/>.
669. Guillain-Barré syndrome after the first dose of Pfizer-BioNTech COVID-19 vaccine: case report and review of reported cases: <https://pubmed.ncbi.nlm.nih.gov/34796417/>.

670. Guillain-Barre syndrome after BNT162b2 COVID-19 vaccine: <https://link.springer.com/article/10.1007%2Fs10072-021-05523-5>.
671. COVID-19 adenovirus vaccines and Guillain-Barré syndrome with facial palsy: <https://onlinelibrary.wiley.com/doi/10.1002/ana.26258>.
672. Association of receipt association of Ad26.COV2.S COVID-19 vaccine with presumed Guillain-Barre syndrome, February-July 2021: <https://jamanetwork.com/journals/jama/fullarticle/2785009>
673. A case of Guillain-Barré syndrome after Pfizer COVID-19 vaccine: <https://pubmed.ncbi.nlm.nih.gov/34567447/>
674. Guillain-Barré syndrome associated with COVID-19 vaccination: <https://pubmed.ncbi.nlm.nih.gov/34648420/>.
675. Rate of recurrent Guillain-Barré syndrome after COVID-19 BNT162b2 mRNA vaccine: <https://jamanetwork.com/journals/jama/neurology/fullarticle/2783708>
676. Guillain-Barre syndrome after COVID-19 vaccination in an adolescent: [https://www.pedneur.com/article/S0887-8994\(21\)00221-6/fulltext](https://www.pedneur.com/article/S0887-8994(21)00221-6/fulltext).
677. Guillain-Barre syndrome after ChAdOx1-S / nCoV-19 vaccination: <https://pubmed.ncbi.nlm.nih.gov/34114256/>.
678. Guillain-Barre syndrome after COVID-19 mRNA-1273 vaccine: case report: <https://pubmed.ncbi.nlm.nih.gov/34767184/>.
679. Guillain-Barre syndrome following SARS-CoV-2 vaccination in 19 patients: <https://pubmed.ncbi.nlm.nih.gov/34644738/>.
680. Guillain-Barre syndrome presenting with facial diplegia following vaccination with COVID-19 in two patients: <https://pubmed.ncbi.nlm.nih.gov/34649856/>
681. A rare case of Guillain-Barré syndrome after COVID-19 vaccination: <https://pubmed.ncbi.nlm.nih.gov/34671572/>
682. Neurological complications of COVID-19: Guillain-Barre syndrome after Pfizer COVID-19 vaccine: <https://pubmed.ncbi.nlm.nih.gov/33758714/>
683. COVID-19 vaccine causing Guillain-Barre syndrome, an uncommon potential side effect: <https://pubmed.ncbi.nlm.nih.gov/34484780/>
684. Guillain-Barre syndrome after the first dose of COVID-19 vaccination: case report; <https://pubmed.ncbi.nlm.nih.gov/34779385/>.
685. Miller Fisher syndrome after Pfizer COVID-19 vaccine: <https://pubmed.ncbi.nlm.nih.gov/34817727/>.
686. Miller Fisher syndrome after 2019 BNT162b2 mRNA coronavirus vaccination: <https://pubmed.ncbi.nlm.nih.gov/34789193/>.
687. Bilateral facial weakness with a variant of paresthesia of Guillain-Barre syndrome after Vaxzevria COVID-19 vaccine: <https://pubmed.ncbi.nlm.nih.gov/34261746/>
688. Guillain-Barre syndrome after the first injection of ChAdOx1 nCoV-19 vaccine: first report: <https://pubmed.ncbi.nlm.nih.gov/34217513/>.
689. A case of sensory ataxic Guillain-Barre syndrome with immunoglobulin G anti-GM1 antibodies after first dose of COVID-19 BNT162b2 mRNA vaccine (Pfizer): <https://pubmed.ncbi.nlm.nih.gov/34871447/>
690. Reporting of acute inflammatory neuropathies with COVID-19 vaccines: subgroup disproportionality analysis in VigiBase: <https://pubmed.ncbi.nlm.nih.gov/34579259/>
691. A variant of Guillain-Barré syndrome after SARS-CoV-2 vaccination: AMSAN: <https://pubmed.ncbi.nlm.nih.gov/34370408/>.
692. A rare variant of Guillain-Barré syndrome after vaccination with Ad26.COV2.S: <https://pubmed.ncbi.nlm.nih.gov/34703690/>.
693. Guillain-Barré syndrome after SARS-CoV-2 vaccination in a patient with previous vaccine-associated Guillain-Barré syndrome: <https://pubmed.ncbi.nlm.nih.gov/34810163/>
694. Guillain-Barré syndrome in an Australian state using mRNA and adenovirus-vector SARS-CoV-2 vaccines: <https://onlinelibrary.wiley.com/doi/10.1002/ana.26218>.
695. Acute transverse myelitis after SARS-CoV-2 vaccination: case report and review of the literature: <https://pubmed.ncbi.nlm.nih.gov/34482455/>.
696. Variant Guillain-Barré syndrome occurring after SARS-CoV-2 vaccination: <https://pubmed.ncbi.nlm.nih.gov/34114269/>.
697. Guillain-Barre syndrome with axonal variant temporally associated with Modern SARS-CoV-2 mRNA-based vaccine: <https://pubmed.ncbi.nlm.nih.gov/34722067/>
698. Guillain-Barre syndrome after the first dose of SARS-CoV-2 vaccine: a temporary occurrence, not a causal association: <https://pubmed.ncbi.nlm.nih.gov/33968610/>
699. SARS-CoV-2 vaccines can be complicated not only by Guillain-Barré syndrome but also by distal small fiber neuropathy: <https://pubmed.ncbi.nlm.nih.gov/34525410/>
700. Clinical variant of Guillain-Barré syndrome with prominent facial diplegia after AstraZeneca 2019 coronavirus disease vaccine: <https://pubmed.ncbi.nlm.nih.gov/34808658/>
701. Adverse event reporting and risk of Bell's palsy after COVID-19 vaccination: [https://www.thelancet.com/journals/laninf/article/PIIS1473-3099\(21\)00646-0/fulltext](https://www.thelancet.com/journals/laninf/article/PIIS1473-3099(21)00646-0/fulltext).
702. Bilateral facial nerve palsy and COVID-19 vaccination: causality or coincidence: <https://pubmed.ncbi.nlm.nih.gov/34522557/>
703. Left Bell's palsy after the first dose of mRNA-1273 SARS-CoV-2 vaccine: case report: <https://pubmed.ncbi.nlm.nih.gov/34763263/>.
704. Bell's palsy after inactivated vaccination with COVID-19 in a patient with a history of recurrent Bell's palsy: case report: <https://pubmed.ncbi.nlm.nih.gov/34621891/>
705. Neurological complications after the first dose of COVID-19 vaccines and SARS-CoV-2 infection: <https://pubmed.ncbi.nlm.nih.gov/34697502/>
706. Type I interferons as a potential mechanism linking COVID-19 mRNA vaccines with Bell's palsy: <https://pubmed.ncbi.nlm.nih.gov/33858693/>
707. Acute transverse myelitis following inactivated COVID-19 vaccine: <https://pubmed.ncbi.nlm.nih.gov/34370410/>
708. Acute transverse myelitis after COVID-19 vaccination: <https://pubmed.ncbi.nlm.nih.gov/34579245/>.
709. A case of longitudinally extensive transverse myelitis following Covid-19 vaccination: <https://pubmed.ncbi.nlm.nih.gov/34182207/>
710. Post COVID-19 transverse myelitis; a case report with review of the literature: <https://pubmed.ncbi.nlm.nih.gov/34457267/>.
711. Beware of neuromyelitis optica spectrum disorder after vaccination with inactivated virus for COVID-19: <https://pubmed.ncbi.nlm.nih.gov/34189662/>
712. Neuromyelitis optica in a healthy woman after vaccination against severe acute respiratory syndrome coronavirus 2 mRNA-1273: <https://pubmed.ncbi.nlm.nih.gov/34660149/>
713. Acute bilateral optic neuritis/chiasm with longitudinal extensive transverse myelitis in long-standing stable multiple sclerosis after vector-based vaccination against SARS-CoV-2: <https://pubmed.ncbi.nlm.nih.gov/34131771/>
714. A case series of acute pericarditis after vaccination with COVID-19 in the context of recent reports from Europe and the United States: <https://pubmed.ncbi.nlm.nih.gov/34635376/>
715. Acute pericarditis and cardiac tamponade after vaccination with Covid-19: <https://pubmed.ncbi.nlm.nih.gov/34749492/>
716. Myocarditis and pericarditis in adolescents after the first and second doses of COVID-19 mRNA vaccines: <https://pubmed.ncbi.nlm.nih.gov/34849667/>
717. Perimyocarditis in adolescents after Pfizer-BioNTech COVID-19 vaccine: <https://pubmed.ncbi.nlm.nih.gov/34319393/>
718. Acute myopericarditis after COVID-19 vaccine in adolescents: <https://pubmed.ncbi.nlm.nih.gov/34589238/>

719. Pericarditis after administration of the BNT162b2 mRNA vaccine COVID-19: <https://pubmed.ncbi.nlm.nih.gov/34149145/>
720. Case report: symptomatic pericarditis post COVID-19 vaccination: <https://pubmed.ncbi.nlm.nih.gov/34693198/>.
721. An outbreak of Still's disease after COVID-19 vaccination in a 34-year-old patient: <https://pubmed.ncbi.nlm.nih.gov/34797392/>
722. Hemophagocytic lymphohistiocytosis following COVID-19 vaccination (ChAdOx1 nCoV-19): <https://pubmed.ncbi.nlm.nih.gov/34862234/>
723. Myocarditis after SARS-CoV-2 mRNA vaccination, a case series: <https://pubmed.ncbi.nlm.nih.gov/34396358/>.
724. Miller-Fisher syndrome and Guillain-Barré syndrome overlap syndrome in a patient after Oxford-AstraZeneca SARS-CoV-2 vaccination: <https://pubmed.ncbi.nlm.nih.gov/34848426/>.
725. Immune-mediated disease outbreaks or new-onset disease in 27 subjects after mRNA/DNA vaccination against SARS-CoV-2: <https://pubmed.ncbi.nlm.nih.gov/33946748/>
726. Post-mortem investigation of deaths after vaccination with COVID-19 vaccines: <https://pubmed.ncbi.nlm.nih.gov/34591186/>
727. Acute kidney injury with macroscopic hematuria and IgA nephropathy after COVID-19 vaccination: <https://pubmed.ncbi.nlm.nih.gov/34352309/>
728. Relapse of immune thrombocytopenia after covid-19 vaccination in young male patient: <https://pubmed.ncbi.nlm.nih.gov/34804803/>.
729. Immune thrombocytopenic purpura associated with COVID-19 mRNA vaccine Pfizer-BioNTech BNT16B2b2: <https://pubmed.ncbi.nlm.nih.gov/34077572/>
730. Retinal hemorrhage after SARS-CoV-2 vaccination: <https://pubmed.ncbi.nlm.nih.gov/34884407/>.
731. Case report: anti-neutrophil cytoplasmic antibody-associated vasculitis with acute renal failure and pulmonary hemorrhage can occur after COVID-19 vaccination: <https://pubmed.ncbi.nlm.nih.gov/34859017/>
732. Intracerebral hemorrhage due to vasculitis following COVID-19 vaccination: case report: <https://pubmed.ncbi.nlm.nih.gov/34783899/>
733. Peduncular, symptomatic cavernous bleeding after immune thrombocytopenia-induced SARS-CoV-2 vaccination: <https://pubmed.ncbi.nlm.nih.gov/34549178/>.
734. Brain death in a vaccinated patient with COVID-19 infection: <https://pubmed.ncbi.nlm.nih.gov/34656887/>
735. Generalized purpura annularis telangiectodes after SARS-CoV-2 mRNA vaccination: <https://pubmed.ncbi.nlm.nih.gov/34236717/>.
736. Lobar hemorrhage with ventricular rupture shortly after the first dose of a SARS-CoV-2 mRNA-based SARS-CoV-2 vaccine: <https://pubmed.ncbi.nlm.nih.gov/34729467/>.
737. A case of outbreak of macroscopic hematuria and IgA nephropathy after SARS-CoV-2 vaccination: <https://pubmed.ncbi.nlm.nih.gov/33932458/>
738. Acral hemorrhage after administration of the second dose of SARS-CoV-2 vaccine. A post-vaccination reaction: <https://pubmed.ncbi.nlm.nih.gov/34092400/742/>.
739. Severe immune thrombocytopenic purpura after SARS-CoV-2 vaccine: <https://pubmed.ncbi.nlm.nih.gov/34754937/>
740. Gross hematuria after severe acute respiratory syndrome coronavirus 2 vaccination in 2 patients with IgA nephropathy: <https://pubmed.ncbi.nlm.nih.gov/33771584/>
741. Autoimmune encephalitis after ChAdOx1-S SARS-CoV-2 vaccination: <https://pubmed.ncbi.nlm.nih.gov/34846583/>
742. COVID-19 vaccine and death: causality algorithm according to the WHO eligibility diagnosis: <https://pubmed.ncbi.nlm.nih.gov/34073536/>
743. Bell's palsy after vaccination with mRNA (BNT162b2) and inactivated (CoronaVac) SARS-CoV-2 vaccines: a case series and a nested case-control study: <https://pubmed.ncbi.nlm.nih.gov/34411532/>
744. Epidemiology of myocarditis and pericarditis following mRNA vaccines in Ontario, Canada: by vaccine product, schedule, and interval: <https://www.medrxiv.org/content/10.1101/2021.12.02.21267156v1>
745. Anaphylaxis following Covid-19 vaccine in a patient with cholinergic urticaria: <https://pubmed.ncbi.nlm.nih.gov/33851711/>
746. Anaphylaxis induced by CoronaVac COVID-19 vaccine: clinical features and results of revaccination: <https://pubmed.ncbi.nlm.nih.gov/34675550/>.
747. Anaphylaxis after Modern COVID-19 vaccine: <https://pubmed.ncbi.nlm.nih.gov/34734159/>.
748. Association of self-reported history of high-risk allergy with allergy symptoms after COVID-19 vaccination: <https://pubmed.ncbi.nlm.nih.gov/34698847/>
749. Sex differences in the incidence of anaphylaxis to LNP-mRNA vaccines COVID-19: <https://pubmed.ncbi.nlm.nih.gov/34020815/>
750. Allergic reactions, including anaphylaxis, after receiving the first dose of Pfizer-BioNTech COVID-19 vaccine – United States, December 14 to 23, 2020: <https://pubmed.ncbi.nlm.nih.gov/33641264/>
751. Allergic reactions, including anaphylaxis, after receiving the first dose of Modern COVID-19 vaccine – United States, December 21, 2020 to January 10, 2021: <https://pubmed.ncbi.nlm.nih.gov/33641268/>
752. Prolonged anaphylaxis to Pfizer 2019 coronavirus disease vaccine: a case report and mechanism of action: <https://pubmed.ncbi.nlm.nih.gov/33834172/>
753. Anaphylaxis reactions to Pfizer BNT162b2 vaccine: report of 3 cases of anaphylaxis following vaccination with Pfizer BNT162b2: <https://pubmed.ncbi.nlm.nih.gov/34579211/>
754. Biphasic anaphylaxis after first dose of 2019 messenger RNA coronavirus disease vaccine with positive polysorbate 80 skin test result: <https://pubmed.ncbi.nlm.nih.gov/34343674/>
755. Acute myocardial infarction and myocarditis after COVID-19 vaccination: <https://pubmed.ncbi.nlm.nih.gov/34586408/>
756. Takotsubo syndrome after COVID-19 vaccination: <https://pubmed.ncbi.nlm.nih.gov/34539938/>.
757. Takotsubo cardiomyopathy after coronavirus 2019 vaccination in patient on maintenance hemodialysis: <https://pubmed.ncbi.nlm.nih.gov/34731486/>.
758. Premature myocardial infarction or side effect of COVID-19 vaccine: <https://pubmed.ncbi.nlm.nih.gov/33824804/>
759. Myocardial infarction, stroke, and pulmonary embolism after BNT162b2 mRNA COVID-19 vaccine in persons aged 75 years or older: <https://pubmed.ncbi.nlm.nih.gov/34807248/>
760. Kounis syndrome type 1 induced by inactivated SARS-COV-2 vaccine: <https://pubmed.ncbi.nlm.nih.gov/34148772/>
761. Acute myocardial infarction within 24 hours after COVID-19 vaccination: is Kounis syndrome the culprit: <https://pubmed.ncbi.nlm.nih.gov/34702550/>
762. Deaths associated with the recently launched SARS-CoV-2 vaccination (Comirnaty®): <https://pubmed.ncbi.nlm.nih.gov/33895650/>
763. Deaths associated with recently launched SARS-CoV-2 vaccination: <https://pubmed.ncbi.nlm.nih.gov/34425384/>
764. A case of acute encephalopathy and non-ST-segment elevation myocardial infarction after vaccination with mRNA-1273: possible adverse effect: <https://pubmed.ncbi.nlm.nih.gov/34703815/>
765. COVID-19 vaccine-induced urticarial vasculitis: <https://pubmed.ncbi.nlm.nih.gov/34369046/>.

766. ANCA-associated vasculitis after Pfizer-BioNTech COVID-19 vaccine: <https://pubmed.ncbi.nlm.nih.gov/34280507/>.
767. New-onset leukocytoclastic vasculitis after COVID-19 vaccine: <https://pubmed.ncbi.nlm.nih.gov/34241833/>
768. Cutaneous small vessel vasculitis after COVID-19 vaccine: <https://pubmed.ncbi.nlm.nih.gov/34529877/>.
769. Outbreak of leukocytoclastic vasculitis after COVID-19 vaccine: <https://pubmed.ncbi.nlm.nih.gov/33928638/>
770. Leukocytoclastic vasculitis after exposure to COVID-19 vaccine: <https://pubmed.ncbi.nlm.nih.gov/34836739/>
771. Vasculitis and bursitis in [18 F] FDG-PET/CT after COVID-19 mRNA vaccine: post hoc ergo propter hoc?; <https://pubmed.ncbi.nlm.nih.gov/34495381/>.
772. Cutaneous lymphocytic vasculitis after administration of COVID-19 mRNA vaccine: <https://pubmed.ncbi.nlm.nih.gov/34327795/>
773. Cutaneous leukocytoclastic vasculitis induced by Sinovac COVID-19 vaccine: <https://pubmed.ncbi.nlm.nih.gov/34660867/>.
774. Case report: ANCA-associated vasculitis presenting with rhabdomyolysis and crescentic Pauci-Immune glomerulonephritis after vaccination with Pfizer-BioNTech COVID-19 mRNA: <https://pubmed.ncbi.nlm.nih.gov/34659268/>
775. Reactivation of IgA vasculitis after vaccination with COVID-19: <https://pubmed.ncbi.nlm.nih.gov/34848431/>
776. Varicella-zoster virus-related small-vessel vasculitis after Pfizer-BioNTech COVID-19 vaccination: <https://pubmed.ncbi.nlm.nih.gov/34310759/>.
777. Imaging in vascular medicine: leukocytoclastic vasculitis after COVID-19 vaccine booster: <https://pubmed.ncbi.nlm.nih.gov/34720009/>
778. A rare case of Henoch-Schönlein purpura after a case report of COVID-19 vaccine: <https://pubmed.ncbi.nlm.nih.gov/34518812/>
779. Cutaneous vasculitis following COVID-19 vaccination: <https://pubmed.ncbi.nlm.nih.gov/34611627/>.
780. Possible case of COVID-19 mRNA vaccine-induced small-vessel vasculitis: <https://pubmed.ncbi.nlm.nih.gov/34705320/>.
781. IgA vasculitis following COVID-19 vaccination in an adult: <https://pubmed.ncbi.nlm.nih.gov/34779011/>
782. Propylthiouracil-induced anti-neutrophil cytoplasmic antibody-associated vasculitis following vaccination with COVID-19: <https://pubmed.ncbi.nlm.nih.gov/34451967/>
783. Coronavirus disease vaccine 2019 (COVID-19) in systemic lupus erythematosus and neutrophil anti-cytoplasmic antibody-associated vasculitis: <https://pubmed.ncbi.nlm.nih.gov/33928459/>
784. Reactivation of IgA vasculitis after COVID-19 vaccination: <https://pubmed.ncbi.nlm.nih.gov/34250509/>
785. Clinical and histopathologic spectrum of delayed adverse skin reactions after COVID-19 vaccination: <https://pubmed.ncbi.nlm.nih.gov/34292611/>.
786. First description of immune complex vasculitis after COVID-19 vaccination with BNT162b2: case report: <https://pubmed.ncbi.nlm.nih.gov/34530771/>.
787. Nephrotic syndrome and vasculitis after SARS-CoV-2 vaccine: true association or circumstantial: <https://pubmed.ncbi.nlm.nih.gov/34245294/>.
788. Occurrence of de novo cutaneous vasculitis after vaccination against coronavirus disease (COVID-19): <https://pubmed.ncbi.nlm.nih.gov/34599716/>.
789. Asymmetric cutaneous vasculitis after COVID-19 vaccination with unusual preponderance of eosinophils: <https://pubmed.ncbi.nlm.nih.gov/34115904/>.
790. Henoch-Schönlein purpura occurring after vaccination with COVID-19: <https://pubmed.ncbi.nlm.nih.gov/34247902/>.
791. Henoch-Schönlein purpura following the first dose of COVID-19 viral vector vaccine: case report: <https://pubmed.ncbi.nlm.nih.gov/34696186/>.
792. Granulomatous vasculitis after AstraZeneca anti-SARS-CoV-2 vaccine: <https://pubmed.ncbi.nlm.nih.gov/34237323/>.
793. Acute retinal necrosis due to varicella zoster virus reactivation after vaccination with BNT162b2 COVID-19 mRNA: <https://pubmed.ncbi.nlm.nih.gov/34851795/>.
794. A case of generalized Sweet's syndrome with vasculitis triggered by recent vaccination with COVID-19: <https://pubmed.ncbi.nlm.nih.gov/34849386/>
795. Small-vessel vasculitis following Oxford-AstraZeneca vaccination against SARS-CoV-2: <https://pubmed.ncbi.nlm.nih.gov/34310763/>
796. Relapse of microscopic polyangiitis after COVID-19 vaccination: case report: <https://pubmed.ncbi.nlm.nih.gov/34251683/>.
797. Cutaneous vasculitis after severe acute respiratory syndrome coronavirus 2 vaccine: <https://pubmed.ncbi.nlm.nih.gov/34557622/>.
798. Recurrent herpes zoster after COVID-19 vaccination in patients with chronic urticaria on cyclosporine treatment – A report of 3 cases: <https://pubmed.ncbi.nlm.nih.gov/34510694/>
799. Leukocytoclastic vasculitis after coronavirus disease vaccination 2019: <https://pubmed.ncbi.nlm.nih.gov/34713472/803>
800. Outbreaks of mixed cryoglobulinemia vasculitis after vaccination against SARS-CoV-2: <https://pubmed.ncbi.nlm.nih.gov/34819272/>
801. Cutaneous small-vessel vasculitis after vaccination with a single dose of Janssen Ad26.CO2.S: <https://pubmed.ncbi.nlm.nih.gov/34337124/>
802. Case of immunoglobulin A vasculitis after vaccination against coronavirus disease 2019: <https://pubmed.ncbi.nlm.nih.gov/34535924/>
803. Rapid progression of angioimmunoblastic T-cell lymphoma after BNT162b2 mRNA booster vaccination: case report: <https://www.frontiersin.org/articles/10.3389/fmed.2021.798095/>
804. COVID-19 mRNA vaccination-induced lymphadenopathy mimics lymphoma progression on FDG PET / CT: <https://pubmed.ncbi.nlm.nih.gov/33591026/>
805. Lymphadenopathy in COVID-19 vaccine recipients: diagnostic dilemma in oncology patients: <https://pubmed.ncbi.nlm.nih.gov/33625300/>
806. Hypermetabolic lymphadenopathy after administration of BNT162b2 mRNA vaccine Covid-19: incidence assessed by [18 F] FDG PET-CT and relevance for study interpretation: <https://pubmed.ncbi.nlm.nih.gov/33774684/>
807. Lymphadenopathy after COVID-19 vaccination: review of imaging findings: <https://pubmed.ncbi.nlm.nih.gov/33985872/>
808. Evolution of bilateral hypermetabolic axillary hypermetabolic lymphadenopathy on FDG PET/CT after 2-dose COVID-19 vaccination: <https://pubmed.ncbi.nlm.nih.gov/34735411/>
809. Lymphadenopathy associated with COVID-19 vaccination on FDG PET/CT: distinguishing features in adenovirus-vectored vaccine: <https://pubmed.ncbi.nlm.nih.gov/34115709/>.
810. COVID-19 vaccination-induced lymphadenopathy in a specialized breast imaging clinic in Israel: analysis of 163 cases: <https://pubmed.ncbi.nlm.nih.gov/34257025/>.
811. COVID-19 vaccine-related axillary lymphadenopathy in breast cancer patients: case series with literature review: <https://pubmed.ncbi.nlm.nih.gov/34836672/>.
812. Coronavirus disease vaccine 2019 mimics lymph node metastases in patients undergoing skin cancer follow-up: a single-center study: <https://pubmed.ncbi.nlm.nih.gov/34280870/>
813. COVID-19 post-vaccination lymphadenopathy: report of fine-needle aspiration biopsy cytologic findings: <https://pubmed.ncbi.nlm.nih.gov>

/34432391/

814. Regional lymphadenopathy after COVID-19 vaccination: review of the literature and considerations for patient management in breast cancer care: <https://pubmed.ncbi.nlm.nih.gov/34731748/>
815. Subclinical axillary lymphadenopathy associated with COVID-19 vaccination on screening mammography: <https://pubmed.ncbi.nlm.nih.gov/34906409/>
816. Adverse events of COVID injection that may occur in children. Acute-onset supraclavicular lymphadenopathy coincident with intramuscular mRNA vaccination against COVID-19 may be related to the injection technique of the vaccine, Spain, January and February 2021: <https://pubmed.ncbi.nlm.nih.gov/33706861/>
817. Supraclavicular lymphadenopathy after COVID-19 vaccination in Korea: serial follow-up by ultrasonography: <https://pubmed.ncbi.nlm.nih.gov/34116295/>
818. Oxford-AstraZeneca COVID-19 vaccination induced lymphadenopathy on [18F] choline PET / CT, not just an FDG finding: <https://pubmed.ncbi.nlm.nih.gov/33661328/>
819. Biphasic anaphylaxis after exposure to the first dose of Pfizer-BioNTech COVID-19 mRNA vaccine COVID-19: <https://pubmed.ncbi.nlm.nih.gov/34050949/>
820. Axillary adenopathy associated with COVID-19 vaccination: imaging findings and follow-up recommendations in 23 women: <https://pubmed.ncbi.nlm.nih.gov/33624520/>
821. A case of cervical lymphadenopathy following COVID-19 vaccination: <https://pubmed.ncbi.nlm.nih.gov/34141500/>
822. Unique imaging findings of neurologic phantosmia after Pfizer-BioNTech COVID-19 vaccination: a case report: <https://pubmed.ncbi.nlm.nih.gov/34096896/>
823. Thrombotic adverse events reported for Moderna, Pfizer, and Oxford-AstraZeneca COVID-19 vaccines: comparison of occurrence and clinical outcomes in the EudraVigilance database: <https://pubmed.ncbi.nlm.nih.gov/34835256/>
824. Unilateral lymphadenopathy after COVID-19 vaccination: a practical management plan for radiologists of all specialties: <https://pubmed.ncbi.nlm.nih.gov/33713605/>
825. Unilateral axillary adenopathy in the setting of COVID-19 vaccination: follow-up: <https://pubmed.ncbi.nlm.nih.gov/34298342/>
826. A systematic review of cases of CNS demyelination following COVID-19 vaccination: <https://pubmed.ncbi.nlm.nih.gov/34839149/>
827. Supraclavicular lymphadenopathy after COVID-19 vaccination: an increasing presentation in the two-week wait neck lump clinic: <https://pubmed.ncbi.nlm.nih.gov/33685772/>
828. COVID-19 vaccine-related axillary and cervical lymphadenopathy in patients with current or previous breast cancer and other malignancies: cross-sectional imaging findings on MRI, CT and PET-CT: <https://pubmed.ncbi.nlm.nih.gov/34719892/>
829. Adenopathy after COVID-19 vaccination: <https://pubmed.ncbi.nlm.nih.gov/33625299/>.
830. Incidence of axillary adenopathy on breast imaging after vaccination with COVID-19: <https://pubmed.ncbi.nlm.nih.gov/34292295/>.
831. COVID-19 vaccination and lower cervical lymphadenopathy in two-week neck lump clinic: a follow-up audit: <https://pubmed.ncbi.nlm.nih.gov/33947605/>.
832. Cervical lymphadenopathy after coronavirus disease vaccination 2019: clinical features and implications for head and neck cancer services: <https://pubmed.ncbi.nlm.nih.gov/34526175/>
833. Lymphadenopathy associated with the COVID-19 vaccine: <https://pubmed.ncbi.nlm.nih.gov/33786231/>
834. Evolution of lymphadenopathy on PET/MRI after COVID-19 vaccination: <https://pubmed.ncbi.nlm.nih.gov/33625301/>.
835. Autoimmune hepatitis triggered by SARS-CoV-2 vaccination: <https://pubmed.ncbi.nlm.nih.gov/34332438/>.
836. New-onset nephrotic syndrome after Janssen COVID-19 vaccination: case report and literature review: <https://pubmed.ncbi.nlm.nih.gov/34342187/>.
837. Massive cervical lymphadenopathy following vaccination with COVID-19: <https://pubmed.ncbi.nlm.nih.gov/34601889/>
838. ANCA glomerulonephritis following Modern COVID-19 vaccination: <https://pubmed.ncbi.nlm.nih.gov/34081948/>
839. Extensive longitudinal transverse myelitis following AstraZeneca COVID-19 vaccination: <https://pubmed.ncbi.nlm.nih.gov/34507942/>.
840. Systemic capillary extravasation syndrome after vaccination with ChAdOx1 nCoV-19 (Oxford-AstraZeneca): <https://pubmed.ncbi.nlm.nih.gov/34362727/>
841. Unilateral axillary lymphadenopathy related to COVID-19 vaccine: pattern on screening breast MRI allowing benign evaluation: <https://pubmed.ncbi.nlm.nih.gov/34325221/>
842. Axillary lymphadenopathy in patients with recent Covid-19 vaccination: a new diagnostic dilemma: <https://pubmed.ncbi.nlm.nih.gov/34825530/>.
843. Minimal change disease and acute kidney injury after Pfizer-BioNTech COVID-19 vaccine: <https://pubmed.ncbi.nlm.nih.gov/34000278/>
844. COVID-19 vaccine-induced unilateral axillary adenopathy: follow-up evaluation in the USA: <https://pubmed.ncbi.nlm.nih.gov/34655312/>.
845. Gastroparesis after Pfizer-BioNTech COVID-19 vaccination: <https://pubmed.ncbi.nlm.nih.gov/34187985/>.
846. Acute-onset supraclavicular lymphadenopathy coincident with intramuscular mRNA vaccination against COVID-19 may be related to the injection technique of the vaccine, Spain, January and February 2021: <https://pubmed.ncbi.nlm.nih.gov/33706861/>
847. Supraclavicular lymphadenopathy after COVID-19 vaccination in Korea: serial follow-up by ultrasonography: <https://pubmed.ncbi.nlm.nih.gov/34116295/>
848. Oxford-AstraZeneca COVID-19 vaccination induced lymphadenopathy on [18F] choline PET / CT, not just an FDG finding: <https://pubmed.ncbi.nlm.nih.gov/33661328/>
849. Biphasic anaphylaxis after exposure to the first dose of Pfizer-BioNTech COVID-19 mRNA vaccine COVID-19: <https://pubmed.ncbi.nlm.nih.gov/34050949/>
850. Axillary adenopathy associated with COVID-19 vaccination: imaging findings and follow-up recommendations in 23 women: <https://pubmed.ncbi.nlm.nih.gov/33624520/>
851. A case of cervical lymphadenopathy following COVID-19 vaccination: <https://pubmed.ncbi.nlm.nih.gov/34141500/>
852. Unique imaging findings of neurologic phantosmia after Pfizer-BioNTech COVID-19 vaccination: a case report: <https://pubmed.ncbi.nlm.nih.gov/34096896/>
853. Thrombotic adverse events reported for Moderna, Pfizer, and Oxford-AstraZeneca COVID-19 vaccines: comparison of occurrence and clinical outcomes in the EudraVigilance database: <https://pubmed.ncbi.nlm.nih.gov/34835256/>
854. Unilateral lymphadenopathy after COVID-19 vaccination: a practical management plan for radiologists of all specialties: <https://pubmed.ncbi.nlm.nih.gov/33713605/>
855. Unilateral axillary adenopathy in the setting of COVID-19 vaccination: follow-up: <https://pubmed.ncbi.nlm.nih.gov/34298342/>

856. A systematic review of cases of CNS demyelination following COVID-19 vaccination: <https://pubmed.ncbi.nlm.nih.gov/34839149/>
857. Supraclavicular lymphadenopathy after COVID-19 vaccination: an increasing presentation in the two-week wait neck lump clinic: <https://pubmed.ncbi.nlm.nih.gov/33685772/>
858. COVID-19 vaccine-related axillary and cervical lymphadenopathy in patients with current or previous breast cancer and other malignancies: cross-sectional imaging findings on MRI, CT and PET-CT: <https://pubmed.ncbi.nlm.nih.gov/34719892/>
859. Adenopathy after COVID-19 vaccination: <https://pubmed.ncbi.nlm.nih.gov/33625299/>.
860. Incidence of axillary adenopathy on breast imaging after vaccination with COVID-19: <https://pubmed.ncbi.nlm.nih.gov/34292295/>.
861. COVID-19 vaccination and lower cervical lymphadenopathy in two-week neck lump clinic: a follow-up audit: <https://pubmed.ncbi.nlm.nih.gov/33947605/>.
862. Cervical lymphadenopathy after coronavirus disease vaccination 2019: clinical features and implications for head and neck cancer services: <https://pubmed.ncbi.nlm.nih.gov/34526175/>
863. Lymphadenopathy associated with the COVID-19 vaccine: <https://pubmed.ncbi.nlm.nih.gov/33786231/>
864. Evolution of lymphadenopathy on PET/MRI after COVID-19 vaccination: <https://pubmed.ncbi.nlm.nih.gov/33625301/>.
865. Autoimmune hepatitis triggered by SARS-CoV-2 vaccination: <https://pubmed.ncbi.nlm.nih.gov/34332438/>.
866. New-onset nephrotic syndrome after Janssen COVID-19 vaccination: case report and literature review: <https://pubmed.ncbi.nlm.nih.gov/34342187/>.
867. Massive cervical lymphadenopathy following vaccination with COVID-19: <https://pubmed.ncbi.nlm.nih.gov/34601889/>
868. ANCA glomerulonephritis following Modern COVID-19 vaccination: <https://pubmed.ncbi.nlm.nih.gov/34081948/>
869. Extensive longitudinal transverse myelitis following AstraZeneca COVID-19 vaccination: <https://pubmed.ncbi.nlm.nih.gov/34507942/>.
870. Systemic capillary extravasation syndrome after vaccination with ChAdOx1 nCoV-19 (Oxford-AstraZeneca): <https://pubmed.ncbi.nlm.nih.gov/34362727/>
871. Unilateral axillary lymphadenopathy related to COVID-19 vaccine: pattern on screening breast MRI allowing benign evaluation: <https://pubmed.ncbi.nlm.nih.gov/34325221/>
872. Axillary lymphadenopathy in patients with recent Covid-19 vaccination: a new diagnostic dilemma: <https://pubmed.ncbi.nlm.nih.gov/34825530/>.
873. Minimal change disease and acute kidney injury after Pfizer-BioNTech COVID-19 vaccine: <https://pubmed.ncbi.nlm.nih.gov/34000278/>
874. COVID-19 vaccine-induced unilateral axillary adenopathy: follow-up evaluation in the USA: <https://pubmed.ncbi.nlm.nih.gov/34655312/>.
875. Gastroparesis after Pfizer-BioNTech COVID-19 vaccination: <https://pubmed.ncbi.nlm.nih.gov/34187985/>.
876. Abbate, A., Gavin, J., Madanchi, N., Kim, C., Shah, P. R., Klein, K., . . . Danielides, S. (2021). Fulminant myocarditis and systemic hyperinflammation temporally associated with BNT162b2 mRNA COVID-19 vaccination in two patients. *Int J Cardiol*, 340, 119-121. doi:10.1016/j.ijcard.2021.08.018. <https://www.ncbi.nlm.nih.gov/pubmed/34416319>
877. Abu Mouch, S., Roguin, A., Hellou, E., Ishai, A., Shoshan, U., Mahamid, L., . . . Berar Yanay, N. (2021). Myocarditis following COVID-19 mRNA vaccination. *Vaccine*, 39(29), 3790-3793. doi:10.1016/j.vaccine.2021.05.087. <https://www.ncbi.nlm.nih.gov/pubmed/34092429>
878. Albert, E., Aurigemma, G., Saucedo, J., & Gerson, D. S. (2021). Myocarditis following COVID-19 vaccination. *Radiol Case Rep*, 16(8), 2142-2145. doi:10.1016/j.radcr.2021.05.033. <https://www.ncbi.nlm.nih.gov/pubmed/34025885>
879. Aye, Y. N., Mai, A. S., Zhang, A., Lim, O. Z. H., Lin, N., Ng, C. H., . . . Chew, N. W. S. (2021). Acute Myocardial Infarction and Myocarditis following COVID-19 Vaccination. *QJM*. doi:10.1093/qjmed/hcab252. <https://www.ncbi.nlm.nih.gov/pubmed/34586408>
880. Azir, M., Inman, B., Webb, J., & Tannenbaum, L. (2021). HCMB Mimic: Focal Myocarditis in an Adolescent Patient After mRNA COVID-19 Vaccine. *J Emerg Med*, 61(6), e129-e132. doi:10.1016/j.jemermed.2021.09.017. <https://www.ncbi.nlm.nih.gov/pubmed/34756746>
881. Barda, N., Dagan, N., Ben-Shlomo, Y., Kepten, E., Waxman, J., Ohana, R., . . . Balicer, R. D. (2021). Safety of the BNT162b2 mRNA Covid-19 Vaccine in a Nationwide Setting. *N Engl J Med*, 385(12), 1078-1090. doi:10.1056/NEJMoa2110475. <https://www.ncbi.nlm.nih.gov/pubmed/34432976>
882. Bhandari, M., Pradhan, A., Vishwakarma, P., & Sethi, R. (2021). Coronavirus and cardiovascular manifestations- getting to the heart of the matter. *World J Cardiol*, 13(10), 556-565. doi:10.4330/wjc.v13.i10.556. <https://www.ncbi.nlm.nih.gov/pubmed/34754400>
883. Bozkurt, B., Kamat, I., & Hotez, P. J. (2021). Myocarditis With COVID-19 mRNA Vaccines. *Circulation*, 144(6), 471-484. doi:10.1161/CIRCULATIONAHA.121.056135. <https://www.ncbi.nlm.nih.gov/pubmed/34281357>
884. Buchhorn, R., Meyer, C., Schulze-Forster, K., Junker, J., & Heidecke, H. (2021). Autoantibody Release in Children after Corona Virus mRNA Vaccination: A Risk Factor of Multisystem Inflammatory Syndrome? *Vaccines (Basel)*, 9(11). doi:10.3390/vaccines9111353. <https://www.ncbi.nlm.nih.gov/pubmed/34835284>
885. Calcaterra, G., Bassareo, P. P., Barilla, F., Romeo, F., & Mehta, J. L. (2022). Concerning the unexpected prothrombotic state following some coronavirus disease 2019 vaccines. *J Cardiovasc Med (Hagerstown)*, 23(2), 71-74. doi:10.2459/JCM.000000000001232. <https://www.ncbi.nlm.nih.gov/pubmed/34366403>
886. Calcaterra, G., Mehta, J. L., de Gregorio, C., Butera, G., Neroni, P., Fanos, V., & Bassareo, P. P. (2021). COVID 19 Vaccine for Adolescents. Concern about Myocarditis and Pericarditis. *Pediatr Rep*, 13(3), 530-533. doi:10.3390/pediatric13030061. <https://www.ncbi.nlm.nih.gov/pubmed/34564344>
887. Chai, Q., Nygaard, U., Schmidt, R. C., Zaremba, T., Moller, A. M., & Thorvig, C. M. (2022). Multisystem inflammatory syndrome in a male adolescent after his second Pfizer-BioNTech COVID-19 vaccine. *Acta Paediatr*, 111(1), 125-127. doi:10.1111/apa.16141. <https://www.ncbi.nlm.nih.gov/pubmed/34617315>
888. Chamling, B., Vehof, V., Drakos, S., Weil, M., Stalling, P., Vahlhaus, C., . . . Yilmaz, A. (2021). Optreden van acute infarctachtige myocarditis na COVID-19-vaccinatie: slechts een toevallige co-incidentie of liever vaccinatie-geassocieerde auto-immuun myocarditis? *Clin Res Cardiol*, 110(11), 1850-1854. doi:10.1007/s00392-021-01916-w. <https://www.ncbi.nlm.nih.gov/pubmed/34333695>
889. Chang, JC en Hawley, HB (2021). Vaccin-geassocieerde trombocytopenie en trombose: veneuze endotheliopathie leidend tot veneuze gecombineerde micro-macrotrrombose. *Medicina (Kaunas)*, 57(11). doi:10.3390/medicina57111163. <https://www.ncbi.nlm.nih.gov/pubmed/34833382>
890. Chelala, L., Jeudy, J., Hossain, R., Rosenthal, G., Pietris, N., & White, C. (2021). Cardiale MRI-bevindingen van myocarditis na COVID-19-mRNA-vaccinatie bij adolescenten. *AJR Am J Roentgenol*. doi:10.2214/AJR.21.26853. <https://www.ncbi.nlm.nih.gov/pubmed/34704459>
891. Choi, S., Lee, S., Seo, JW, Kim, MJ, Jeon, YH, Park, JH, . . . Yeo, NS (2021). Myocarditis-geïnduceerde plotselinge dood na BNT162b2 mRNA COVID-19-vaccinatie in Korea: casusrapport gericht op histopathologische bevindingen. *J Koreaanse Med Sci*, 36(40), e286. doi:10.3346/jkms.2021.36.e286. <https://www.ncbi.nlm.nih.gov/pubmed/34664804>
892. Chouchana, L., Blet, A., Al-Khalaf, M., Kafil, TS, Nair, G., Robblee, J., . . . Liu, PP (2021). Kenmerken van inflammatoire hartreacties na

- mRNA COVID-19-vaccinatie op mondiaal niveau. *Clin Pharmacol Ther.* doi:10.1002/cpt.2499. <https://www.ncbi.nlm.nih.gov/pubmed/34860360>
893. Chua, GT, Kwan, MYW, Chui, CSL, Smith, RD, Cheung, EC, Tian, T., . . . Ip, P. (2021). Epidemiologie van acute myocarditis/pericarditis bij adolescenten in Hong Kong na vaccinatie in de Comirnaty. *Clin Infect Dis.* doi:10.1093/cid/ciab989. <https://www.ncbi.nlm.nih.gov/pubmed/34849657>
894. Clarke, R., en Ioannou, A. (2021). Moet T2-mapping worden gebruikt in gevallen van recidiverende myocarditis om onderscheid te maken tussen acute ontsteking en chronisch litteken? *J Pediatr.* doi:10.1016/j.jpeds.2021.12.026. <https://www.ncbi.nlm.nih.gov/pubmed/34933012>
895. Colaneri, M., De Filippo, M., Licari, A., Marseglia, A., Maiocchi, L., Ricciardi, A., . . . Bruno, R. (2021). COVID-vaccinatie en astma-exacerbatie: zou er een verband kunnen zijn? *Int J Infect Dis.* 112, 243-246. doi:10.1016/j.ijid.2021.09.026. <https://www.ncbi.nlm.nih.gov/pubmed/34547487>
896. Das, BB, Kohli, U., Ramachandran, P., Nguyen, HH, Greil, G., Hussain, T., . . . Khan, D. (2021). Myopericarditis na vaccinatie tegen messenger RNA Coronavirus Disease 2019 bij adolescenten van 12 tot 18 jaar. *J Pediatr.* 238, 26-32 e21. doi:10.1016/j.jpeds.2021.07.044. <https://www.ncbi.nlm.nih.gov/pubmed/34339728>
897. Das, BB, Moskowitz, WB, Taylor, MB, & Palmer, A. (2021). Myocarditis en pericarditis na mRNA COVID-19-vaccinatie: wat weten we tot nu toe? *Kinderen (Basel)*, 8(7). doi:10.3390/kinderen8070607. <https://www.ncbi.nlm.nih.gov/pubmed/34356586>
898. Deb, A., Abdelmalek, J., Luwji, K., & Nugent, K. (2021). Acuut myocardletsel na COVID-19-vaccinatie: een casusrapport en beoordeling van het huidige bewijs uit de database van het rapportagesysteem voor bijwerkingen van vaccins. *J Prim Care Community Health*, 12, 21501327211029230. doi:10.1177/21501327211029230. <https://www.ncbi.nlm.nih.gov/pubmed/34219532>
899. Dickey, JB, Albert, E., Badr, M., Laraja, KM, Sena, LM, Gerson, DS, . . . Aurigemina, huisarts (2021). Een reeks patiënten met myocarditis na SARS-CoV-2-vaccinatie met mRNA-1279 en BNT162b2. *JACC Cardiovasc-beeldvorming*, 14(9), 1862-1863. doi:10.1016/j.jcmg.2021.06.003. <https://www.ncbi.nlm.nih.gov/pubmed/34246585>
900. Dimopoulou, D., Spyridis, N., Vartzelis, G., Tsolia, MN, & Maritsi, DN (2021). Veiligheid en verdraagbaarheid van het COVID-19 mRNA-vaccin bij adolescenten met juveniele idiopathische artritis die worden behandeld met TNF-remmers. *Arthritis Reumatol.* doi:10.1002/art.41977. <https://www.ncbi.nlm.nih.gov/pubmed/34492161>
901. Dimopoulou, D., Vartzelis, G., Dasoula, F., Tsolia, M., & Maritsi, D. (2021). Immunogeniciteit van het COVID-19-mRNA-vaccin bij adolescenten met juveniele idiopathische artritis die worden behandeld met TNF-remmers. *Ann Reum Dis.* doi:10.1136/annrheumdis-2021-221607. <https://www.ncbi.nlm.nih.gov/pubmed/34844930>
902. Ehrlich, P., Klingel, K., Ohlmann-Knafo, S., Hutter, S., Sood, N., Pickuth, D., & Kindermann, M. (2021). Door biopsie bewezen lymfatische myocarditis na de eerste mRNA COVID-19-vaccinatie bij een 40-jarige man: casusrapport. *Clin Res Cardiol*, 110(11), 1855-1859. doi:10.1007/s00392-021-01936-6. <https://www.ncbi.nlm.nih.gov/pubmed/34487236>
903. El Sahly, HM, Baden, LR, Essink, B., Doblecki-Lewis, S., Martin, JM, Anderson, EJ, . . . Groep, CS (2021). Werkzaamheid van het mRNA-1273 SARS-CoV-2-vaccin bij voltooiing van de geblyndeerde fase. *N Engl J Med*, 385(19), 1774-1785. doi:10.1056/NEJMoa2113017. <https://www.ncbi.nlm.nih.gov/pubmed/34551225>
904. Facetti, S., Giraldo, M., Vecchi, AL, Rogiani, S., & Nassiacos, D. (2021). [Acute myocarditis bij een jongvolwassene twee dagen na vaccinatie met Pfizer]. *G Ital Cardiol (Rome)*, 22(11), 891-893. doi:10.1714/3689.36746. <https://www.ncbi.nlm.nih.gov/pubmed/34709227>
905. Fazlollahi, A., Zahmatyar, M., Noori, M., Nejadghaderi, SA, Sullman, MJM, Shekarriz-Foumani, R., . . . Safiri, S. (2021). Hartcomplicaties na mRNA COVID-19-vaccins: een systematische review van casusrapporten en casusreeksen. *Rev Med Virol*, e2318. doi:10.1002/rmv.2318. <https://www.ncbi.nlm.nih.gov/pubmed/34921468>
906. Fazolo, T., Lima, K., Fontoura, JC, de Souza, PO, Hilario, G., Zorzetto, R., . . . Bonorino, C. (2021). Pediatric COVID-19-patiënten in Zuid-Brazilië vertonen overvloedig viraal mRNA en sterke specifieke antivirale reacties. *Nat Commun*, 12(1), 6844. doi:10.1038/s41467-021-27120-y. <https://www.ncbi.nlm.nih.gov/pubmed/34824230>
907. Fikenzler, S., & Laufs, U. (2021). Correctie op: Reactie op brief aan de redactie die verwijst naar Fikenzler, S., Uhe, T., Lavall, D., Rudolph, U., Falz, R., Busse, M., Hepp, P., & Laufs, U (2020). Effecten van chirurgische en FFP2/N95-gezichtsmaskers op cardiopulmonale inspanningscapaciteit. *Klinisch onderzoek in de cardiologie: officieel tijdschrift van de Duitse Cardiac Society*, 1-9. Vooraf online publicatie. <https://doi.org/10.1007/s00392-020-01704-y>. *Clin Res Cardiol*, 110(8), 1352. doi:10.1007/s00392-021-01896-x. <https://www.ncbi.nlm.nih.gov/pubmed/34170372>
908. Foltran, D., Delmas, C., Flumian, C., De Paoli, P., Salvo, F., Gautier, S., . . . Montastruc, F. (2021). Myocarditis and Pericarditis in Adolescents after First and Second doses of mRNA COVID-19 Vaccines. *Eur Heart J Qual Care Clin Outcomes.* doi:10.1093/ehjqcco/qcab090. <https://www.ncbi.nlm.nih.gov/pubmed/34849667>
909. Forgacs, D., Jang, H., Abreu, RB, Hanley, HB, Gattiker, JL, Jefferson, AM, & Ross, TM (2021). SARS-CoV-2 mRNA-vaccins lokken verschillende reacties uit bij immunologisch naïeve en pre-immuun mensen. *Front Immunol*, 12, 728021. doi:10.3389/fimmu.2021.728021. <https://www.ncbi.nlm.nih.gov/pubmed/34646267>
910. Furer, V., Eviatar, T., Zisman, D., Peleg, H., Paran, D., Levartovsky, D., . . . Elkayam, O. (2021). Immunogeniciteit en veiligheid van het BNT162b2 mRNA COVID-19-vaccin bij volwassen patiënten met auto-immuun inflammatoire reumatische aandoeningen en bij de algemene bevolking: een multicenter studie. *Ann Rheum Dis*, 80(10), 1330-1338. doi:10.1136/annrheumdis-2021-220647. <https://www.ncbi.nlm.nih.gov/pubmed/34127481>
911. Galindo, R., Chow, H., & Rongkavilit, C. (2021). COVID-19 bij kinderen: klinische manifestaties en farmacologische interventies, waaronder vaccanonderzoeken. *Pediatr Clin North Am*, 68(5), 961-976. doi:10.1016/j.pcl.2021.05.004. <https://www.ncbi.nlm.nih.gov/pubmed/34538306>
912. Gargano, JW, Wallace, M., Hadler, SC, Langley, G., Su, JR, Oster, ME, . . . Oliver, SE (2021). Gebruik van mRNA COVID-19-vaccin na meldingen van myocarditis onder ontvangers van vaccins: update van het Raadgevend Comité voor immunisatiepraktijken – Verenigde Staten, juni 2021. *MMWR Morb Mortal Wkly Rep*, 70(27), 977-982. doi:10.15585/mmwr.mm7027e2. <https://www.ncbi.nlm.nih.gov/pubmed/34237049>
913. Gatti, M., Raschi, E., Moretti, U., Ardizzoni, A., Poluzzi, E., & Diemberger, I. (2021). Influenza Vaccination and Myo-Pericarditis in Patients Receiving Immune Checkpoint Inhibitors: Investigating the Likelihood of Interaction through the Vaccine Adverse Event Reporting System and VigiBase. *Vaccines (Basel)*, 9(1). doi:10.3390/vaccines9010019. <https://www.ncbi.nlm.nih.gov/pubmed/33406694>
914. Gautam, N., Saluja, P., Fudim, M., Jambhekar, K., Pandey, T., & Al'Aref, S. (2021). A Late Presentation of COVID-19 Vaccine-Induced Myocarditis. *Cureus*, 13(9), e17890. doi:10.7759/cureus.17890. <https://www.ncbi.nlm.nih.gov/pubmed/34660088>
915. Gellad, W. F. (2021). Myocarditis after vaccination against covid-19. *BMJ*, 375, n3090. doi:10.1136/bmj.n3090. <https://www.ncbi.nlm.nih.gov/pubmed/34916217>
916. Greenhawt, M., Abrams, E. M., Shaker, M., Chu, D. K., Khan, D., Akin, C., . . . Golden, D. B. K. (2021). The Risk of Allergic Reaction to

- SARS-CoV-2 Vaccines and Recommended Evaluation and Management: A Systematic Review, Meta-Analysis, GRADE Assessment, and International Consensus Approach. *J Allergy Clin Immunol Pract*, 9(10), 3546-3567. doi:10.1016/j.jaip.2021.06.006. <https://www.ncbi.nlm.nih.gov/pubmed/34153517>
917. Haaf, P., Kuster, G. M., Mueller, C., Berger, C. T., Monney, P., Burger, P., . . . Tanner, F. C. (2021). The very low risk of myocarditis and pericarditis after mRNA COVID-19 vaccination should not discourage vaccination. *Swiss Med Wkly*, 151, w30087. doi:10.4414/smw.2021.w30087. <https://www.ncbi.nlm.nih.gov/pubmed/34668687>
918. Hasnie, A. A., Hasnie, U. A., Patel, N., Aziz, M. U., Xie, M., Lloyd, S. G., & Prabhu, S. D. (2021). Perimyocarditis following first dose of the mRNA-1273 SARS-CoV-2 (Moderna) vaccine in a healthy young male: a case report. *BMC Cardiovasc Disord*, 21(1), 375. doi:10.1186/s12872-021-02183-3. <https://www.ncbi.nlm.nih.gov/pubmed/34348657>
919. Hause, A. M., Gee, J., Baggs, J., Abara, W. E., Marquez, P., Thompson, D., . . . Shay, D. K. (2021). COVID-19 Vaccine Safety in Adolescents Aged 12-17 Years – United States, December 14, 2020-July 16, 2021. *MMWR Morb Mortal Wkly Rep*, 70(31), 1053-1058. doi:10.15585/mmwr.mm7031e1. <https://www.ncbi.nlm.nih.gov/pubmed/34351881>
920. Helms, J. M., Ansteatt, K. T., Roberts, J. C., Kamatam, S., Foong, K. S., Labayog, J. S., & Tarantino, M. D. (2021). Severe, Refractory Immune Thrombocytopenia Occurring After SARS-CoV-2 Vaccine. *J Blood Med*, 12, 221-224. doi:10.2147/JBM.S307047. <https://www.ncbi.nlm.nih.gov/pubmed/33854395>
921. Hippisley-Cox, J., Patone, M., Mei, X. W., Saatci, D., Dixon, S., Khunti, K., . . . Coupland, C. A. C. (2021). Risk of thrombocytopenia and thromboembolism after covid-19 vaccination and SARS-CoV-2 positive testing: self-controlled case series study. *BMJ*, 374, n1931. doi:10.1136/bmj.n1931. <https://www.ncbi.nlm.nih.gov/pubmed/34446426>
922. Ho, J. S., Sia, C. H., Ngiam, J. N., Loh, P. H., Chew, N. W., Kong, W. K., & Poh, K. K. (2021). A review of COVID-19 vaccination and the reported cardiac manifestations. *Singapore Med J*. doi:10.11622/smedj.2021210. <https://www.ncbi.nlm.nih.gov/pubmed/34808708>
923. Iguchi, T., Umeda, H., Kojima, M., Kanno, Y., Tanaka, Y., Kinoshita, N., & Sato, D. (2021). Cumulative Adverse Event Reporting of Anaphylaxis After mRNA COVID-19 Vaccine (Pfizer-BioNTech) Injections in Japan: The First-Month Report. *Drug Saf*, 44(11), 1209-1214. doi:10.1007/s40264-021-01104-9. <https://www.ncbi.nlm.nih.gov/pubmed/34347278>
924. In brief: Myocarditis with the Pfizer/BioNTech and Moderna COVID-19 vaccines. (2021). *Med Lett Drugs Ther*, 63(1629), e9. Retrieved from <https://www.ncbi.nlm.nih.gov/pubmed/34544112><https://www.ncbi.nlm.nih.gov/pubmed/3454412>
925. Ioannou, A. (2021a). Myocarditis should be considered in those with a troponin rise and unobstructed coronary arteries following Pfizer-BioNTech COVID-19 vaccination. *QJM*. doi:10.1093/qjmed/hcab231. <https://www.ncbi.nlm.nih.gov/pubmed/34463755>
926. Ioannou, A. (2021b). T2 mapping should be utilised in cases of suspected myocarditis to confirm an acute inflammatory process. *QJM*. doi:10.1093/qjmed/hcab326. <https://www.ncbi.nlm.nih.gov/pubmed/34931681>
927. Isaak, A., Feisst, A., & Luetkens, J. A. (2021). Myocarditis Following COVID-19 Vaccination. *Radiology*, 301(1), E378-E379. doi:10.1148/radiol.20211211766. <https://www.ncbi.nlm.nih.gov/pubmed/34342500>
928. Istampoulouglou, I., Dimitriou, G., Spani, S., Christ, A., Zimmermanns, B., Koechlin, S., . . . Leuppi-Taegtmeier, A. B. (2021). Myocarditis and pericarditis in association with COVID-19 mRNA-vaccination: cases from a regional pharmacovigilance centre. *Glob Cardiol Sci Pract*, 2021(3), e202118. doi:10.21542/gcsp.2021.18. <https://www.ncbi.nlm.nih.gov/pubmed/34805376>
929. Jaafar, R., Boschi, C., Aherfi, S., Bancod, A., Le Bideau, M., Edouard, S., . . . La Scola, B. (2021). High Individual Heterogeneity of Neutralizing Activities against the Original Strain and Nine Different Variants of SARS-CoV-2. *Viruses*, 13(11). doi:10.3390/v13112177. <https://www.ncbi.nlm.nih.gov/pubmed/34834983>
930. Jain, S. S., Steele, J. M., Fonseca, B., Huang, S., Shah, S., Maskatia, S. A., . . . Grosse-Wortmann, L. (2021). COVID-19 Vaccination-Associated Myocarditis in Adolescents. *Pediatrics*, 148(5). doi:10.1542/peds.2021-053427. <https://www.ncbi.nlm.nih.gov/pubmed/34389692>
931. Jhaveri, R., Adler-Shohet, F. C., Blyth, C. C., Chiotos, K., Gerber, J. S., Green, M., . . . Zaoutis, T. (2021). Weighing the Risks of Perimyocarditis With the Benefits of SARS-CoV-2 mRNA Vaccination in Adolescents. *J Pediatric Infect Dis Soc*, 10(10), 937-939. doi:10.1093/jpids/piab061. <https://www.ncbi.nlm.nih.gov/pubmed/34270752>
932. Kaneta, K., Yokoi, K., Jojima, K., Kotooka, N., & Node, K. (2021). Young Male With Myocarditis Following mRNA-1273 Vaccination Against Coronavirus Disease-2019 (COVID-19). *Circ J*. doi:10.1253/circj.CJ-21-0818. <https://www.ncbi.nlm.nih.gov/pubmed/34744118>
933. Kaul, R., Sreenivasan, J., Goel, A., Malik, A., Bandyopadhyay, D., Jin, C., . . . Panza, J. A. (2021). Myocarditis following COVID-19 vaccination. *Int J Cardiol Heart Vasc*, 36, 100872. doi:10.1016/j.ijcha.2021.100872. <https://www.ncbi.nlm.nih.gov/pubmed/34568540>
934. Khogali, F., & Abdelrahman, R. (2021). Unusual Presentation of Acute Perimyocarditis Following SARS-COV-2 mRNA-1237 Moderna Vaccination. *Cureus*, 13(7), e16590. doi:10.7759/cureus.16590. <https://www.ncbi.nlm.nih.gov/pubmed/34447639>
935. Kim, H. W., Jenista, E. R., Wendell, D. C., Azevedo, C. F., Campbell, M. J., Darty, S. N., . . . Kim, R. J. (2021). Patients With Acute Myocarditis Following mRNA COVID-19 Vaccination. *JAMA Cardiol*, 6(10), 1196-1201. doi:10.1001/jamacardio.2021.2828. <https://www.ncbi.nlm.nih.gov/pubmed/34185046>
936. Kim, I. C., Kim, H., Lee, H. J., Kim, J. Y., & Kim, J. Y. (2021). Cardiac Imaging of Acute Myocarditis Following COVID-19 mRNA Vaccination. *J Korean Med Sci*, 36(32), e229. doi:10.3346/jkms.2021.36.e229. <https://www.ncbi.nlm.nih.gov/pubmed/34402228>
937. King, W. W., Petersen, M. R., Matar, R. M., Budweg, J. B., Cuervo Pardo, L., & Petersen, J. W. (2021). Myocarditis following mRNA vaccination against SARS-CoV-2, a case series. *Am Heart J Plus*, 8, 100042. doi:10.1016/j.ahjo.2021.100042. <https://www.ncbi.nlm.nih.gov/pubmed/34396358>
938. Klein, N. P., Lewis, N., Goddard, K., Fireman, B., Zerbo, O., Hanson, K. E., . . . Weintraub, E. S. (2021). Surveillance for Adverse Events After COVID-19 mRNA Vaccination. *JAMA*, 326(14), 1390-1399. doi:10.1001/jama.2021.15072. <https://www.ncbi.nlm.nih.gov/pubmed/34477808>
939. Klimek, L., Bergmann, K. C., Brehler, R., Pflutzner, W., Zuberbier, T., Hartmann, K., . . . Worm, M. (2021). Practical handling of allergic reactions to COVID-19 vaccines: A position paper from German and Austrian Allergy Societies AeDA, DGAKI, GPA and OGAI. *Allergo J Int*, 1-17. doi:10.1007/s40629-021-00165-7. <https://www.ncbi.nlm.nih.gov/pubmed/33898162>
940. Klimek, L., Novak, N., Hamelmann, E., Werfel, T., Wagenmann, M., Taube, C., . . . Worm, M. (2021). Severe allergic reactions after COVID-19 vaccination with the Pfizer/BioNTech vaccine in Great Britain and USA: Position statement of the German Allergy Societies: Medical Association of German Allergologists (AeDA), German Society for Allergy and Clinical Immunology (DGAKI) and Society for Pediatric Allergy and Environmental Medicine (GPA). *Allergo J Int*, 30(2), 51-55. doi:10.1007/s40629-020-00160-4. <https://www.ncbi.nlm.nih.gov/pubmed/33643776>
941. Kohli, U., Desai, L., Chowdhury, D., Harahsheh, A. S., Yonts, A. B., Ansong, A., . . . Ang, J. Y. (2021). mRNA Coronavirus-19 Vaccine-Associated Myopericarditis in Adolescents: A Survey Study. *J Pediatr*. doi:10.1016/j.jpeds.2021.12.025. <https://www.ncbi.nlm.nih.gov/pubmed/34952008>

942. Kostoff, R. N., Calina, D., Kanduc, D., Briggs, M. B., Vlachoyiannopoulos, P., Svistunov, A. A., & Tsatsakis, A. (2021a). Erratum to "Why are we vaccinating children against COVID-19?" [Toxicol. Rep. 8C (2021) 1665-1684 / 1193]. *Toxicol Rep*, 8, 1981. doi:10.1016/j.toxrep.2021.10.003. <https://www.ncbi.nlm.nih.gov/pubmed/34642628>
943. Kostoff, R. N., Calina, D., Kanduc, D., Briggs, M. B., Vlachoyiannopoulos, P., Svistunov, A. A., & Tsatsakis, A. (2021b). Why are we vaccinating children against COVID-19? *Toxicol Rep*, 8, 1665-1684. doi:10.1016/j.toxrep.2021.08.010. <https://www.ncbi.nlm.nih.gov/pubmed/34540594>
944. Kremsner, P. G., Mann, P., Kroidl, A., Leroux-Roels, I., Schindler, C., Gabor, J. J., . . . Group, C.-N.-S. (2021). Safety and immunogenicity of an mRNA-lipid nanoparticle vaccine candidate against SARS-CoV-2 : A phase 1 randomized clinical trial. *Wien Klin Wochenschr*, 133(17-18), 931-941. doi:10.1007/s00508-021-01922-y. <https://www.ncbi.nlm.nih.gov/pubmed/34378087>
945. Kustin, T., Harel, N., Finkel, U., Perchik, S., Harari, S., Tahor, M., . . . Stern, A. (2021). Evidence for increased breakthrough rates of SARS-CoV-2 variants of concern in BNT162b2-mRNA-vaccinated individuals. *Nat Med*, 27(8), 1379-1384. doi:10.1038/s41591-021-01413-7. <https://www.ncbi.nlm.nih.gov/pubmed/34127854>
946. Kwan, M. Y. W., Chua, G. T., Chow, C. B., Tsao, S. S. L., To, K. K. W., Yuen, K. Y., . . . Ip, P. (2021). mRNA COVID vaccine and myocarditis in adolescents. *Hong Kong Med J*, 27(5), 326-327. doi:10.12809/hkmj215120. <https://www.ncbi.nlm.nih.gov/pubmed/34393110>
947. Lee, E., Chew, N. W. S., Ng, P., & Yeo, T. J. (2021). Reply to "Letter to the editor: Myocarditis should be considered in those with a troponin rise and unobstructed coronary arteries following PfizerBioNTech COVID-19 vaccination". *QJM*. doi:10.1093/qjmed/hcab232. <https://www.ncbi.nlm.nih.gov/pubmed/34463770>
948. Lee, E. J., Cines, D. B., Gernsheimer, T., Kessler, C., Michel, M., Tarantino, M. D., . . . Bussel, J. B. (2021). Thrombocytopenia following Pfizer and Moderna SARS-CoV-2 vaccination. *Am J Hematol*, 96(5), 534-537. doi:10.1002/ajh.26132. <https://www.ncbi.nlm.nih.gov/pubmed/33606296>
949. Levin, D., Shimon, G., Fadlon-Derai, M., Gershovitz, L., Shovali, A., Sebbag, A., . . . Gordon, B. (2021). Myocarditis na COVID-19-vaccinatie - Een casusreeks. *Vaccin*, 39(42), 6195-6200. doi:10.1016/j.vaccin.2021.09.004. <https://www.ncbi.nlm.nih.gov/pubmed/34535317>
950. Li, J., Hui, A., Zhang, X., Yang, Y., Tang, R., Ye, H., . . . Zhu, F. (2021). Veiligheid en immunogeniciteit van het SARS-CoV-2 BNT162b1 mRNA-vaccin bij jongere en oudere Chinese volwassenen: een gerandomiseerde, placebogecontroleerde, dubbelblinde fase 1-studie. *Nat Med*, 27(6), 1062-1070. doi:10.1038/s41591-021-01330-9. <https://www.ncbi.nlm.nih.gov/pubmed/33888900>
951. Li, M., Yuan, J., Lv, G., Brown, J., Jiang, X., & Lu, ZK (2021). Myocarditis en pericarditis na COVID-19-vaccinatie: ongelijkheden in leeftijd en vaccintypes. *J Persmed*, 11(11). doi:10.3390/jpm11111106. <https://www.ncbi.nlm.nih.gov/pubmed/34834458>
952. Lim, Y., Kim, MC, Kim, KH, Jeong, IS, Cho, YS, Choi, YD, & Lee, JE (2021). Casusrapport: acute fulminante myocarditis en cardiogene shock na vaccinatie tegen Messenger RNA-coronavirusziekte 2019 waarvoor extracorporale cardiopulmonale reanimatie vereist is. *Front Cardiovasc Med*, 8, 758996. doi:10.3389/fcvm.2021.758996. <https://www.ncbi.nlm.nih.gov/pubmed/34778411>
953. Lang, SS (2021). Belangrijke inzichten in myopericarditis na de Pfizer mRNA COVID-19-vaccinatie bij adolescenten. *J Pediatr*, 238, 5. doi:10.1016/j.jpeds.2021.07.057. <https://www.ncbi.nlm.nih.gov/pubmed/34332972>
954. Luk, A., Clarke, B., Dahdah, N., Ducharme, A., Krahn, A., McCrindle, B., . . . McDonald, M. (2021). Myocarditis en pericarditis na COVID-19 mRNA-vaccinatie: praktische overwegingen voor zorgverleners. *Can J Cardiol*, 37(10), 1629-1634. doi:10.1016/j.cjca.2021.08.001. <https://www.ncbi.nlm.nih.gov/pubmed/34375696>
955. Madelon, N., Lauper, K., Breville, G., Sabater Royo, I., Goldstein, R., Andrey, DO, . . . Eberhardt, CS (2021). Robuuste T-celresponsen bij met anti-CD20 behandelde patiënten na COVID-19-vaccinatie: een prospectieve cohortstudie. *Clin Infect Dis*. doi:10.1093/cid/ciab954. <https://www.ncbi.nlm.nih.gov/pubmed/34791081>
956. Mangat, C., en Milosavljevic, N. (2021). BNT162b2-vaccinatie tijdens de zwangerschap beschermt zowel de moeder als het kind: anti-SARS-CoV-2 S-antilichamen aanhoudend positief bij een kind van 6 maanden oud. *Case Rep Pediatr*, 2021, 6901131. doi:10.1155/2021/6901131. <https://www.ncbi.nlm.nih.gov/pubmed/34676123>
957. Mark, C., Gupta, S., Punnett, A., Upton, J., Orkin, J., Atkinson, A., . . . Alexander, S. (2021). Veiligheid van toediening van BNT162b2-mRNA (Pfizer-BioNTech) COVID-19-vaccin bij jongeren en jongvolwassenen met een voorgeschiedenis van acute lymfoblastische leukemie en allergie voor PEG-asparaginase. *Bloedkanker bij kinderen*, 68(11), e29295. doi:10.1002/pbc.29295. <https://www.ncbi.nlm.nih.gov/pubmed/34398511>
958. Martins-Filho, PR, Quintans-Junior, LJ, de Souza Araujo, AA, Sposato, KB, Souza Tavares, CS, Gurgel, RQ, . . . Santos, VS (2021). Sociaal-economische ongelijkheden en incidentie en mortaliteit van COVID-19 bij Braziliaanse kinderen: een landelijke, op registers gebaseerde studie. *Volksgezondheid*, 190, 4-6. doi:10.1016/j.puhe.2020.11.005. <https://www.ncbi.nlm.nih.gov/pubmed/33316478>
959. McLean, K., & Johnson, TJ (2021). Myopericarditis bij een voorheen gezonde adolescente man na COVID-19-vaccinatie: een casusrapport. *Acad Emerg Med*, 28(8), 918-921. doi:10.1111/acem.14322. <https://www.ncbi.nlm.nih.gov/pubmed/34133825>
960. Mevorach, D., Anis, E., Cedar, N., Bromberg, M., Haas, EJ, Nadir, E., . . . Alroy-Preis, S. (2021). Myocarditis na BNT162b2 mRNA-vaccin tegen Covid-19 in Israël. *N Engl J Med*, 385(23), 2140-2149. doi:10.1056/NEJMoa2109730. <https://www.ncbi.nlm.nih.gov/pubmed/34614328>
961. Minocha, PK, Better, D., Singh, RK, & Hoque, T. (2021). Herhaling van acute myocarditis tijdelijk geassocieerd met ontvangst van het mRNA Coronavirus Disease 2019 (COVID-19) vaccin bij een mannelijke adolescent. *J Pediatr*, 238, 321-323. doi:10.1016/j.jpeds.2021.06.035. <https://www.ncbi.nlm.nih.gov/pubmed/34166671>
962. Mizrahi, B., Lotan, R., Kalkstein, N., Peretz, A., Perez, G., Ben-Tov, A., . . . Patalon, T. (2021). Correlatie van SARS-CoV-2-doorbraakinfecties met tijd vanaf vaccin. *Nat Commun*, 12(1), 6379. doi:10.1038/s41467-021-26672-3. <https://www.ncbi.nlm.nih.gov/pubmed/34737312>
963. Moffitt, K., Cheung, E., Yeung, T., Stamoulis, C., & Malley, R. (2021). Analyse van *Staphylococcus aureus* Transcriptome in pediatrische wekedelenabcessen en vergelijking met muizeninfecties. *Infecteer Immun*, 89(4). doi:10.1128/IAI.00715-20. <https://www.ncbi.nlm.nih.gov/pubmed/33526560>
964. Mohamed, L., Madsen, AMR, Schaltz-Buchholzer, F., Ostefeld, A., Netea, MG, Benn, CS, & Kofoed, PE (2021). Reactivering van BCG-vaccinatie-lictekens na vaccinatie met mRNA-Covid-vaccins: twee casusrapporten. *BMC Infect Dis*, 21(1), 1264. doi:10.1186/s12879-021-06949-0. <https://www.ncbi.nlm.nih.gov/pubmed/34930152>
965. Montgomery, J., Ryan, M., Engler, R., Hoffman, D., McClenathan, B., Collins, L., . . . Cooper, LT, Jr. (2021). Myocarditis na immunisatie met mRNA COVID-19-vaccins bij leden van het Amerikaanse leger. *JAMA Cardiol*, 6(10), 1202-1206. doi:10.1001/jamacardio.2021.2833. <https://www.ncbi.nlm.nih.gov/pubmed/34185045>
966. Murakami, Y., Shinohara, M., Oka, Y., Wada, R., Noike, R., Ohara, H., . . . Ikeda, T. (2021). Myocarditis na een COVID-19 Messenger RNA-vaccinatie: een Japanse casusreeks. *Stagiaire Med*. doi:10.2169/internalmedicine.8731-21. <https://www.ncbi.nlm.nih.gov/pubmed/34840235>
967. Nagasaka, T., Koitabashi, N., Ishibashi, Y., Aihara, K., Takama, N., Ohyama, Y., . . . Kaneko, Y. (2021). Acute myocarditis geassocieerd met

- COVID-19-vaccinatie: een casusrapport. *J Cardio-gevallen*. doi:10.1016/j.jccase.2021.11.006. <https://www.ncbi.nlm.nih.gov/pubmed/34876937>
968. Ntoulos, PA, Vlachogiannis, NI, Pappa, M., Nezos, A., Mavragani, CP, Tektonidou, MG, . . . Sfikakis, PP (2021). Effectieve reactie op DNA-schade na acute maar niet chronische immuunuitdaging: SARS-CoV-2-vaccin versus systemische lupus erythematosus. *Clin Immunol*, 229, 108765. doi:10.1016/j.clim.2021.108765. <https://www.ncbi.nlm.nih.gov/pubmed/34089859>
969. Nygaard, U., Holm, M., Bohnstedt, C., Chai, Q., Schmidt, LS, Hartling, UB, . . . Stensballe, LG (2022). Populatie-gebaseerde incidentie van myopericarditis na COVID-19-vaccinatie bij Deense adolescenten. *Pediatr Infect Dis J*, 41(1), e25-e28. doi:10.1097/INF.0000000000003389. <https://www.ncbi.nlm.nih.gov/pubmed/34889875>
970. Oberhardt, V., Luxenburger, H., Kemming, J., Schulien, I., Ciminski, K., Giese, S., . . . Hofmann, M. (2021). Snelle en stabiele mobilisatie van CD8(+) T-cellen door SARS-CoV-2 mRNA-vaccin. *Natuur*, 597(7875), 268-273. doi:10.1038/s41586-021-03841-4. <https://www.ncbi.nlm.nih.gov/pubmed/34320609>
971. Park, H., Yun, KW, Kim, KR, Song, SH, Ahn, B., Kim, DR, . . . Kim, YJ (2021). Epidemiologie en klinische kenmerken van myocarditis/pericarditis vóór de introductie van mRNA COVID-19-vaccin bij Koreaanse kinderen: een multicenter-onderzoek. *J Koreaanse Med Sci*, 36(32), e232. doi:10.3346/jkms.2021.36.e232. <https://www.ncbi.nlm.nih.gov/pubmed/34402230>
972. Park, J., Brekke, DR, & Bratincsak, A. (2021). Zelfbeperkte myocarditis met pijn op de borst en verhoging van het ST-segment bij adolescenten na vaccinatie met het BNT162b2-mRNA-vaccin. *Cardiol Jong*, 1-4. doi:10.1017/S1047951121002547. <https://www.ncbi.nlm.nih.gov/pubmed/34180390>
973. Patel, YR, Louis, DW, Atalay, M., Agarwal, S., & Shah, NR (2021). Bevindingen van cardiovasculaire magnetische resonantie bij jongvolwassen patiënten met acute myocarditis na mRNA COVID-19-vaccinatie: een casusreeks. *J Cardiovasc Magn Reson*, 23(1), 101. doi:10.1186/s12968-021-00795-4. <https://www.ncbi.nlm.nih.gov/pubmed/34496880>
974. Patone, M., Mei, XW, Handunnetthi, L., Dixon, S., Zaccardi, F., Shankar-Hari, M., . . . Hippisley-Cox, J. (2021). Risico's op myocarditis, pericarditis en hartritme stoornissen geassocieerd met COVID-19-vaccinatie of SARS-CoV-2-infectie. *Nat Med*. doi:10.1038/s41591-021-01630-0. <https://www.ncbi.nlm.nih.gov/pubmed/34907393>
975. Patrignani, A., Schicchi, N., Calcagnoli, F., Falchetti, E., Ciampani, N., Argalia, G., & Mariani, A. (2021). Acute myocarditis na Comirnaty-vaccinatie bij een gezonde man met eerdere SARS-CoV-2-infectie. *Radiol Case Rep*, 16(11), 3321-3325. doi:10.1016/j.radcr.2021.07.082. <https://www.ncbi.nlm.nih.gov/pubmed/34367386>
976. Perez, Y., Levy, ER, Joshi, AY, Virk, A., Rodriguez-Porcel, M., Johnson, M., . . . Snel, MD (2021). Myocarditis na COVID-19 mRNA-vaccin: een casusreeks en bepaling van de incidentie. *Clin Infect Dis*. doi:10.1093/cid/ciab926. <https://www.ncbi.nlm.nih.gov/pubmed/34734240>
977. Perrotta, A., Biondi-Zoccai, G., Saade, W., Miraldi, F., Morelli, A., Marullo, AG, . . . Peruzzi, M. (2021). Een momentopname van een wereldwijd onderzoek naar bijwerkingen van COVID-19-vaccins onder beroepsbeoefenaren in de gezondheidszorg en strijdkrachten, met de nadruk op hoofdpijn. *Panminerva Med*, 63(3), 324-331. doi:10.23736/S0031-0808.21.04435-9. <https://www.ncbi.nlm.nih.gov/pubmed/34738774>
978. Pinana, JL, Lopez-Corral, L., Martino, R., Montoro, J., Vazquez, L., Perez, A., . . . Celtherapie, G. (2022). SARS-CoV-2-reactieve antilichaamdetectie na SARS-CoV-2-vaccinatie bij ontvangers van hematopoëtische stamceltransplantaties: prospectief onderzoek van de Spaanse hematopoëtische stamceltransplantatie- en celtherapiegroep. *Am J Hematol*, 97(1), 30-42. doi:10.1002/ajh.26385. <https://www.ncbi.nlm.nih.gov/pubmed/34695229>
979. Revon-Riviere, G., Ninove, L., Min, V., Rome, A., Coze, C., Verschuur, A., . . . André, N. (2021). Het BNT162b2-mRNA COVID-19-vaccin bij adolescenten en jongvolwassenen met kanker: een monocentrische ervaring. *Eur J Kreeft*, 154, 30-34. doi:10.1016/j.ejca.2021.06.002. <https://www.ncbi.nlm.nih.gov/pubmed/34233234>
980. Sanchez Tijmes, F., Thavendiranathan, P., Udell, JA, Seidman, MA, & Hanneman, K. (2021). Cardiale MRI-beoordeling van niet-ischemische myocardontsteking: overzicht van de stand van de techniek en update over myocarditis geassocieerd met COVID-19-vaccinatie. *Radiol Cardiothoracale beeldvorming*, 3(6), e210252. doi:10.1148/ryct.210252. <https://www.ncbi.nlm.nih.gov/pubmed/34934954>
981. Schauer, J., Buddhe, S., Colyer, J., Sagiv, E., Law, Y., Mallenahalli Chikkabyrappa, S., & Portman, MA (2021). Myopericarditis na het Pfizer Messenger Ribonucleic Acid Coronavirus Disease-vaccin bij adolescenten. *J Pediatr*, 238, 317-320. doi:10.1016/j.jpeds.2021.06.083. <https://www.ncbi.nlm.nih.gov/pubmed/34228985>
982. Schneider, J., Sottmann, L., Greinacher, A., Hagen, M., Kasper, HU, Kuhnen, C., . . . Schmeling, A. (2021). Postmortaal onderzoek naar dodelijke slachtoffers na vaccinatie met COVID-19-vaccins. *Int J Legal Med*, 135(6), 2335-2345. doi:10.1007/s00414-021-02706-9. <https://www.ncbi.nlm.nih.gov/pubmed/34591186>
983. Schramm, R., Costard-Jackle, A., Rivinius, R., Fischer, B., Muller, B., Boeken, U., . . . Gummert, J. (2021). Slechte humorale en T-celrespons op SARS-CoV-2-messenger-RNA-vaccin BNT162b2 met twee doses bij ontvangers van een cardiothoracale transplantatie. *Clin Res Cardiol*, 110(8), 1142-1149. doi:10.1007/s00392-021-01880-5. <https://www.ncbi.nlm.nih.gov/pubmed/34241676>
984. Sessa, F., Salerno, M., Esposito, M., Di Nunno, N., Zamboni, P., & Pomara, C. (2021). Autopsiebevindingen en oorzakelijk verband tussen overlijden en COVID-19-vaccinatie: een systematische review. *J. Clin Med*, 10(24). doi:10.3390/jcm10245876. <https://www.ncbi.nlm.nih.gov/pubmed/34945172>
985. Sharif, N., Alzahrani, KJ, Ahmed, SN, & Dey, SK (2021). Werkzaamheid, immunogeniciteit en veiligheid van COVID-19-vaccins: een systematische review en meta-analyse. *Front Immunol*, 12, 714170. doi:10.3389/fimmu.2021.714170. <https://www.ncbi.nlm.nih.gov/pubmed/34707602>
986. Shay, DK, Gee, J., Su, JR, Myers, TR, Marquez, P., Liu, R., . . . Shimabukuro, TT (2021). Veiligheidsbewaking van het Janssen (Johnson & Johnson) COVID-19-vaccin - Verenigde Staten, maart-april 2021. *MMWR Morb Mortal Wkly Rep*, 70(18), 680-684. doi:10.15585/mmwr.mm7018e2. <https://www.ncbi.nlm.nih.gov/pubmed/33956784>
987. Shazley, O., & Alshazley, M. (2021). Een COVID-positieve 52-jarige man gepresenteerd met veneuze trombo-embolie en gedissemineerde intravasculaire stolling na Johnson & Johnson-vaccinatie: een casestudy. *Cureus*, 13(7), e16383. doi:10.7759/cureus.16383. <https://www.ncbi.nlm.nih.gov/pubmed/34408937>
988. Shiyovich, A., Witberg, G., Aviv, Y., Eisen, A., Orvin, K., Wiessman, M., . . . Hamdan, A. (2021). Myocarditis na COVID-19-vaccinatie: onderzoek naar magnetische resonantiebeeldvorming. *Eur Heart J Cardiovasc-beeldvorming*. doi:10.1093/ehjci/jeab230. <https://www.ncbi.nlm.nih.gov/pubmed/34739045>
989. Simone, A., Herald, J., Chen, A., Gulati, N., Shen, AY, Lewin, B., & Lee, MS (2021). Acute myocarditis na COVID-19-mRNA-vaccinatie bij volwassenen van 18 jaar of ouder. *JAMA Intern Med*, 181(12), 1668-1670. doi:10.1001/jamainternmed.2021.5511. <https://www.ncbi.nlm.nih.gov/pubmed/34605853>
990. Singer, ME, Taub, IB, & Kaelber, DC (2021). Risico op myocarditis door COVID-19-infectie bij mensen jonger dan 20 jaar: een

- populatiegebaseerde analyse. medRxiv. doi:10.1101/2021.07.23.21260998. <https://www.ncbi.nlm.nih.gov/pubmed/34341797>
991. Smith, C., Odd, D., Harwood, R., Ward, J., Linney, M., Clark, M., . . . Fraser, L. K. (2021). Deaths in children and young people in England after SARS-CoV-2 infection during the first pandemic year. *Nat Med*. doi:10.1038/s41591-021-01578-1. <https://www.ncbi.nlm.nih.gov/pubmed/34764489>
992. Snapiri, O., Rosenberg Danziger, C., Shirman, N., Weissbach, A., Lowenthal, A., Ayalon, I., . . . Bilavsky, E. (2021). Transient Cardiac Injury in Adolescents Receiving the BNT162b2 mRNA COVID-19 Vaccine. *Pediatr Infect Dis J*, 40(10), e360-e363. doi:10.1097/INF.0000000000003235. <https://www.ncbi.nlm.nih.gov/pubmed/34077949>
993. Spinner, J. A., Julien, C. L., Olayinka, L., Dreyer, W. J., Bocchini, C. E., Munoz, F. M., & Devaraj, S. (2021). SARS-CoV-2 anti-spike antibodies after vaccination in pediatric heart transplantation: A first report. *J Heart Lung Transplant*. doi:10.1016/j.healun.2021.11.001. <https://www.ncbi.nlm.nih.gov/pubmed/34911654>
994. Starekova, J., Bluemke, D. A., Bradham, W. S., Grist, T. M., Schiebler, M. L., & Reeder, S. B. (2021). Myocarditis Associated with mRNA COVID-19 Vaccination. *Radiology*, 301(2), E409-E411. doi:10.1148/radiol.2021211430. <https://www.ncbi.nlm.nih.gov/pubmed/34282971>
995. Sulemankhil, I., Abdelrahman, M., & Negi, S. I. (2021). Temporal association between the COVID-19 Ad26.COV2.S vaccine and acute myocarditis: A case report and literature review. *Cardiovasc Revasc Med*. doi:10.1016/j.carrev.2021.08.012. <https://www.ncbi.nlm.nih.gov/pubmed/34420869>
996. Tailor, P. D., Feighery, A. M., El-Sabawi, B., & Prasad, A. (2021). Case report: acute myocarditis following the second dose of mRNA-1273 SARS-CoV-2 vaccine. *Eur Heart J Case Rep*, 5(8), ytab319. doi:10.1093/ehjcr/ytab319. <https://www.ncbi.nlm.nih.gov/pubmed/34514306>
997. Takeda, M., Ishio, N., Shoji, T., Mori, N., Matsumoto, M., & Shikama, N. (2021). Eosinofiele myocarditis na vaccinatie tegen coronaviruziekte 2019 (COVID-19). *Circ J*. doi:10.1253/circj.CJ-21-0935. <https://www.ncbi.nlm.nih.gov/pubmed/34955479>
998. Team, CC-R., Voedsel en medicijnen, A. (2021). Allergische reacties, waaronder anafylaxie na ontvangst van de eerste dosis Pfizer-BioNTech COVID-19-vaccin – Verenigde Staten, 14-23 december 2020. *MMWR Morb Mortal Wkly Rep*, 70(2), 46-51. doi:10.15585/mmwr.mm7002e1. <https://www.ncbi.nlm.nih.gov/pubmed/33444297>
999. Thompson, MG, Burgess, JL, Naleway, AL, Tyner, H., Yoon, SK, Meece, J., . . . Gaglani, M. (2021). Preventie en verzwakking van Covid-19 met de BNT162b2- en mRNA-1273-vaccins. *N Engl J Med*, 385(4), 320-329. doi:10.1056/NEJMoa2107058. <https://www.ncbi.nlm.nih.gov/pubmed/34192428>
1000. Tinoco, M., Leite, S., Faria, B., Cardoso, S., Von Hafe, P., Dias, G., . . . Lourenco, A. (2021). Perimyocarditis na COVID-19-vaccinatie. *Clin Med Insights Cardiol*, 15, 11795468211056634. doi:10.1177/11795468211056634. <https://www.ncbi.nlm.nih.gov/pubmed/34866957>
1001. Truong, DT, Dionne, A., Muniz, JC, McHugh, KE, Portman, MA, Lambert, LM, . . . Newburger, JW (2021). Klinisch vermoede myocarditis tijdelijk gerelateerd aan COVID-19-vaccinatie bij adolescenten en jongvolwassenen. *Circulatie*. doi:10.1161/CIRCULATIONAHA.121.056583. <https://www.ncbi.nlm.nih.gov/pubmed/34865500>
1002. Tutor, A., Unis, G., Ruiz, B., Bolaji, OA, & Bob-Manuel, T. (2021). Spectrum van vermoedelijke cardiomyopathie als gevolg van COVID-19: een casusreeks. *Curr Probl Cardiol*, 46(10), 100926. doi:10.1016/j.cpcardiol.2021.100926. <https://www.ncbi.nlm.nih.gov/pubmed/34311983>
1003. Umei, TC, Kishino, Y., Shiraiishi, Y., Inohara, T., Yuasa, S., & Fukuda, K. (2021). Herhaling van myopericarditis na mRNA COVID-19-vaccinatie bij een mannelijke adolescent. *CJC geopend*. doi:10.1016/j.cjco.2021.12.002. <https://www.ncbi.nlm.nih.gov/pubmed/34904134>
1004. Vidula, MK, Ambrose, M., Glassberg, H., Chokshi, N., Chen, T., Ferrari, VA, & Han, Y. (2021). Myocarditis en andere cardiovasculaire complicaties van de op mRNA gebaseerde COVID-19-vaccins. *Cureus*, 13(6), e15576. doi:10.7759/cureus.15576. <https://www.ncbi.nlm.nih.gov/pubmed/34277198>
1005. Visclosky, T., Theyyuni, N., Klekowski, N., & Bradin, S. (2021). Myocarditis na mRNA COVID-19-vaccin. *Pediatr Emerg Care*, 37(11), 583-584. doi:10.1097/PEC.0000000000002557. <https://www.ncbi.nlm.nih.gov/pubmed/34731877>
1006. Warren, CM, Snow, TT, Lee, AS, Shah, MM, Heider, A., Blomkalns, A., . . . Nadeau, KC (2021). Beoordeling van allergische en anafylactische reacties op mRNA COVID-19-vaccins met bevestigende tests in een Amerikaans regionaal gezondheidssysteem. *JAMA Netw Open*, 4(9), e2125524. doi:10.1001/jamanetworkopen.2021.25524. <https://www.ncbi.nlm.nih.gov/pubmed/34533570>
1007. Watkins, K., Griffin, G., Septaric, K., & Simon, EL (2021). Myocarditis na BNT162b2-vaccinatie bij een gezonde man. *Am J Emerg Med*, 50, 815 e811-815 e812. doi:10.1016/j.ajem.2021.06.051. <https://www.ncbi.nlm.nih.gov/pubmed/34229940>
1008. Weitzman, ER, Sherman, AC, & Levy, O. (2021). SARS-CoV-2-mRNA-vaccinatie zoals uitgedrukt in openbaar commentaar van de Amerikaanse FDA: behoefte aan een publiek-private samenwerking in een lerend immunisatiesysteem. *Front Volksgezondheid*, 9, 695807. doi:10.3389/fpubh.2021.695807. <https://www.ncbi.nlm.nih.gov/pubmed/34336774>
1009. Welsh, KJ, Baumblatt, J., Chege, W., Goud, R., & Nair, N. (2021). Trombocytopenie inclusief immuuntrombocytopenie na ontvangst van mRNA COVID-19-vaccins gemeld aan het Vaccine Adverse Event Reporting System (VAERS). *Vaccin*, 39(25), 3329-3332. doi:10.1016/j.vaccin.2021.04.054. <https://www.ncbi.nlm.nih.gov/pubmed/34006408>
1010. Witberg, G., Barda, N., Hoss, S., Richter, I., Wiessman, M., Aviv, Y., . . . Kornowski, R. (2021). Myocarditis na Covid-19-vaccinatie in een grote zorgorganisatie. *N Engl J Med*, 385(23), 2132-2139. doi:10.1056/NEJMoa2110737. <https://www.ncbi.nlm.nih.gov/pubmed/34614329>
1011. Zimmermann, P., & Curtis, N. (2020). Waarom is COVID-19 minder ernstig bij kinderen? Een overzicht van de voorgestelde mechanismen die ten grondslag liggen aan het leeftijdsgerelateerde verschil in ernst van SARS-CoV-2-infecties. *Aarts Dis Kind*. doi:10.1136/archdischild-2020-320338. <https://www.ncbi.nlm.nih.gov/pubmed/33262177>

*

READ MORE: 57 topwetenschappers en artsen publiceren schokkend onderzoek naar COVID-vaccins en eisen onmiddellijke stopzetting van alle vaccinaties

Opmerking voor lezers: klik op de deelknoppen hierboven of hieronder. Volg ons op Instagram, @crg_globalresearch. Stuur dit artikel door naar uw e-maillijsten. Crosspost op uw blogsite, internetfora. enz.

Uitgelichte afbeelding is van Children's Health Defense

De oorspronkelijke bron van dit artikel is SUN
Copyright © ZON , ZON , 2023

Reageer op Global Research-artikelen op onze Facebook-pagina